

Alopecia Areata-Like Pattern

A New Unifying Concept

¹Curtis T. Thompson, M.D. and ²Athanassios Kolivras, M.D., Ph.D

¹Departments of Biomedical Engineering, Dermatology and Pathology
Oregon Health and Sciences University, Portland, Oregon

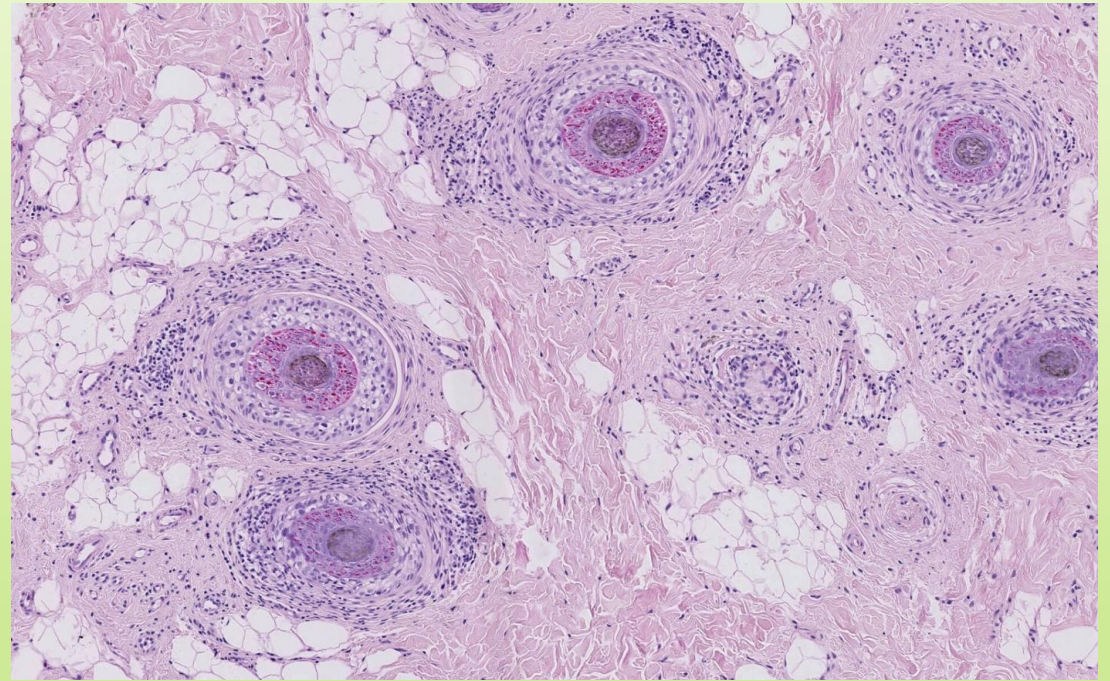
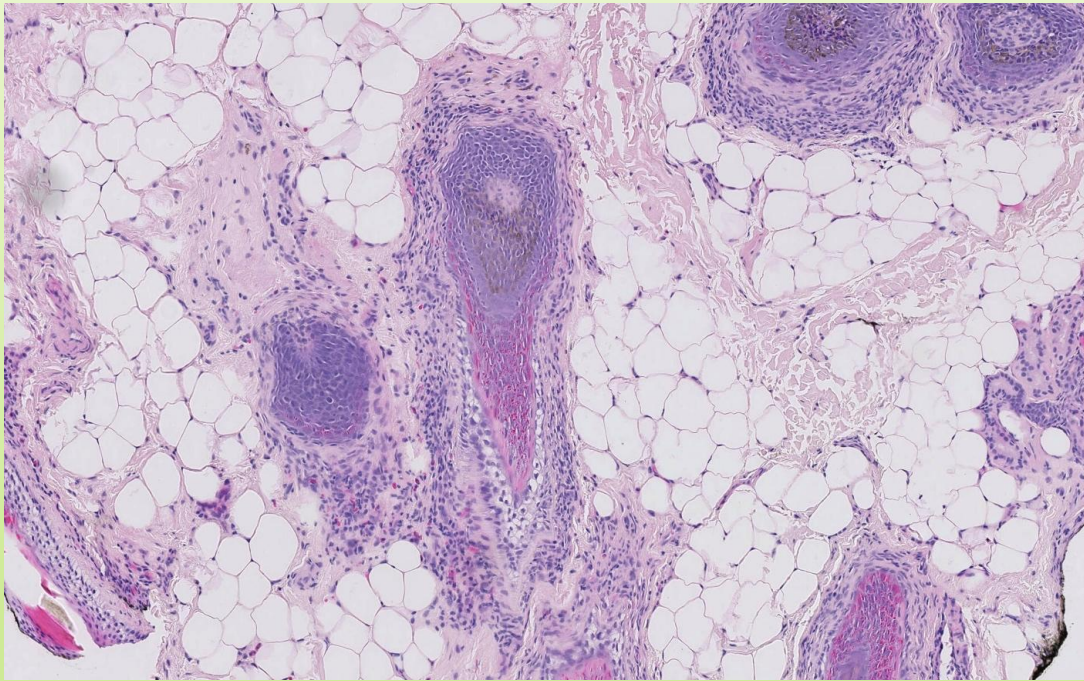
²Saint-Pierre, Brugmann and HUDERF Hospitals
Université Libre de Bruxelles, Brussels, Belgium

We have no industry conflict of interest*

Alopecia Areata-Like Pattern

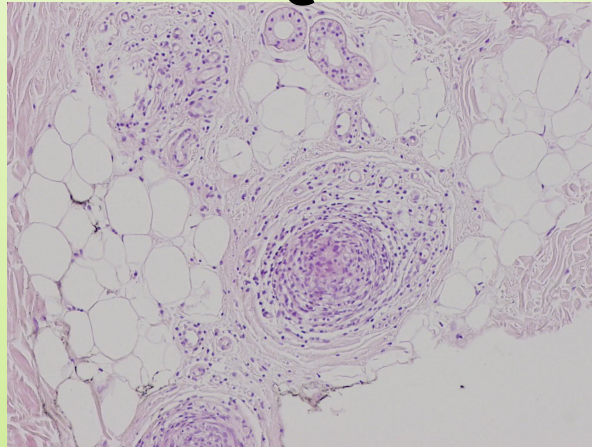
- Important to prevent misdiagnosis
- New, unifying concept of alopecia based upon **hair follicle immunology and follicular cell kinetics** rather than the nature of the inflammatory cell infiltrate

Acute Alopecia Areata




Alopecia Areata

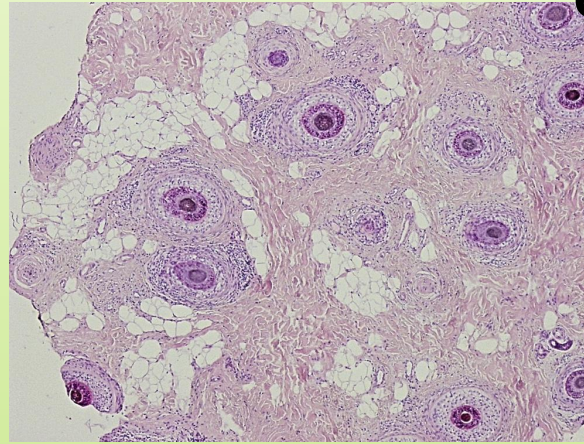
Acute



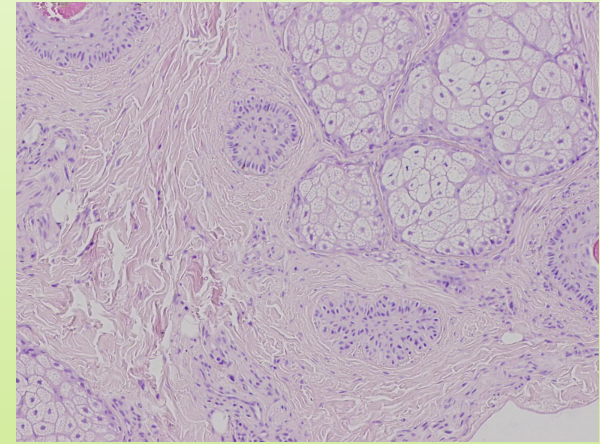
Peribulbar
lymphocytic
infiltrate



Subacute

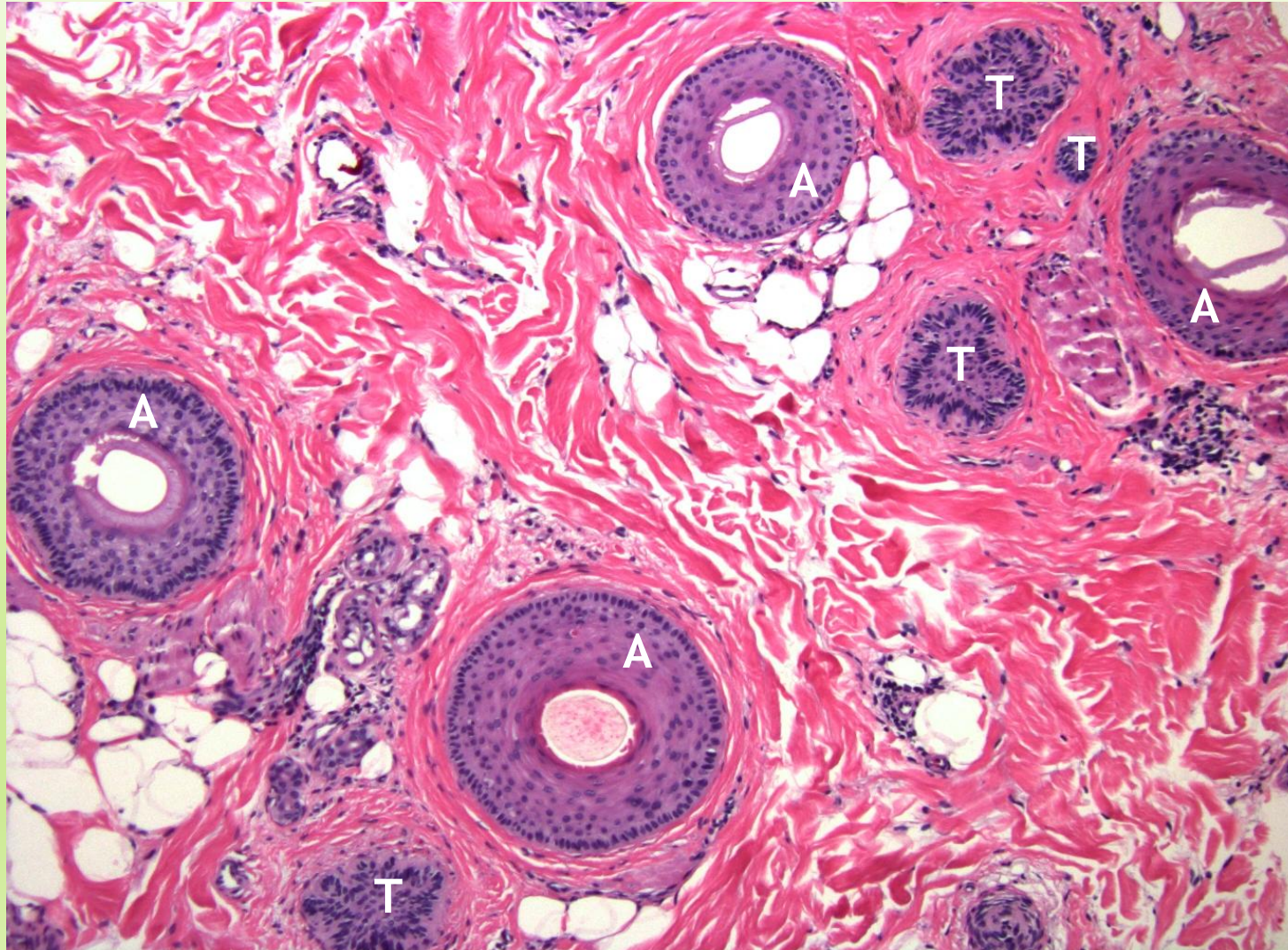


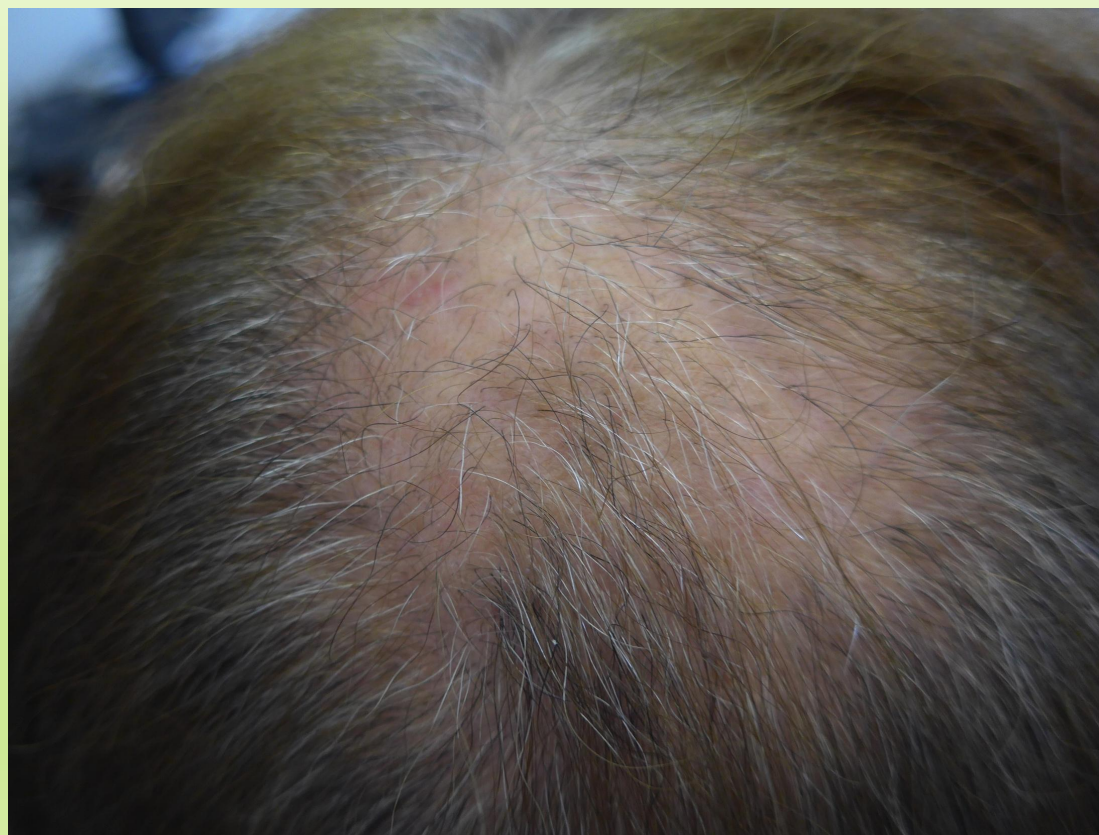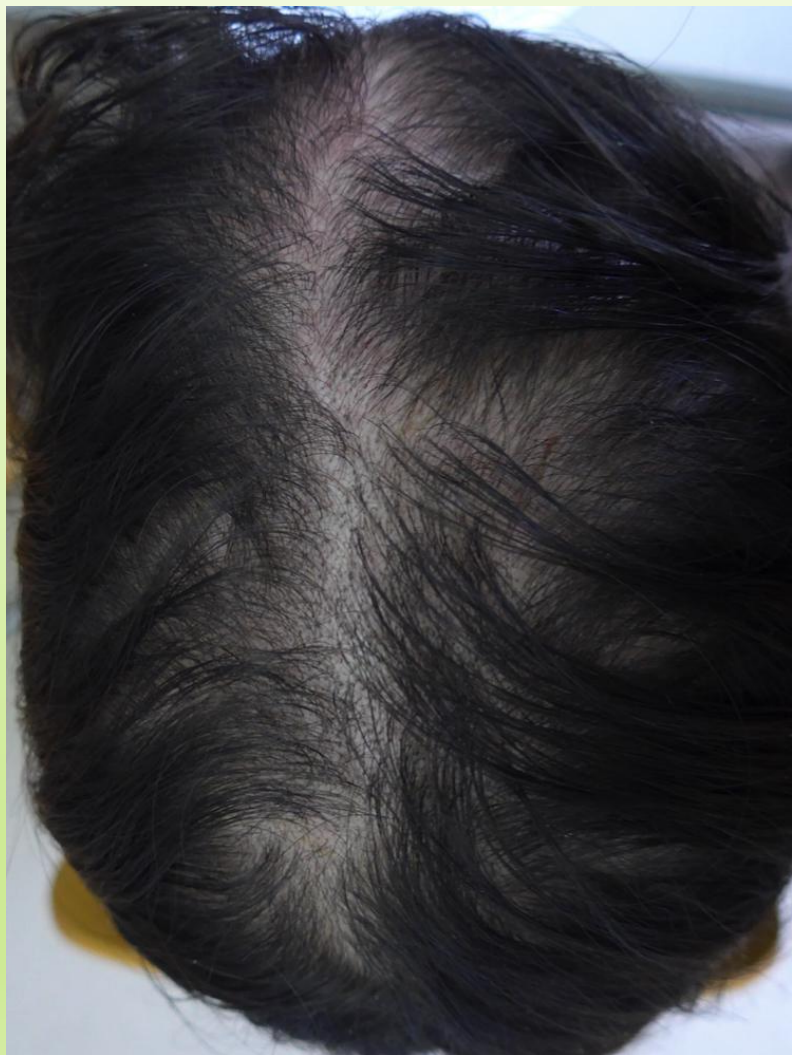Marked
Follicular
Miniaturization
 $T:V \leq 1:7$

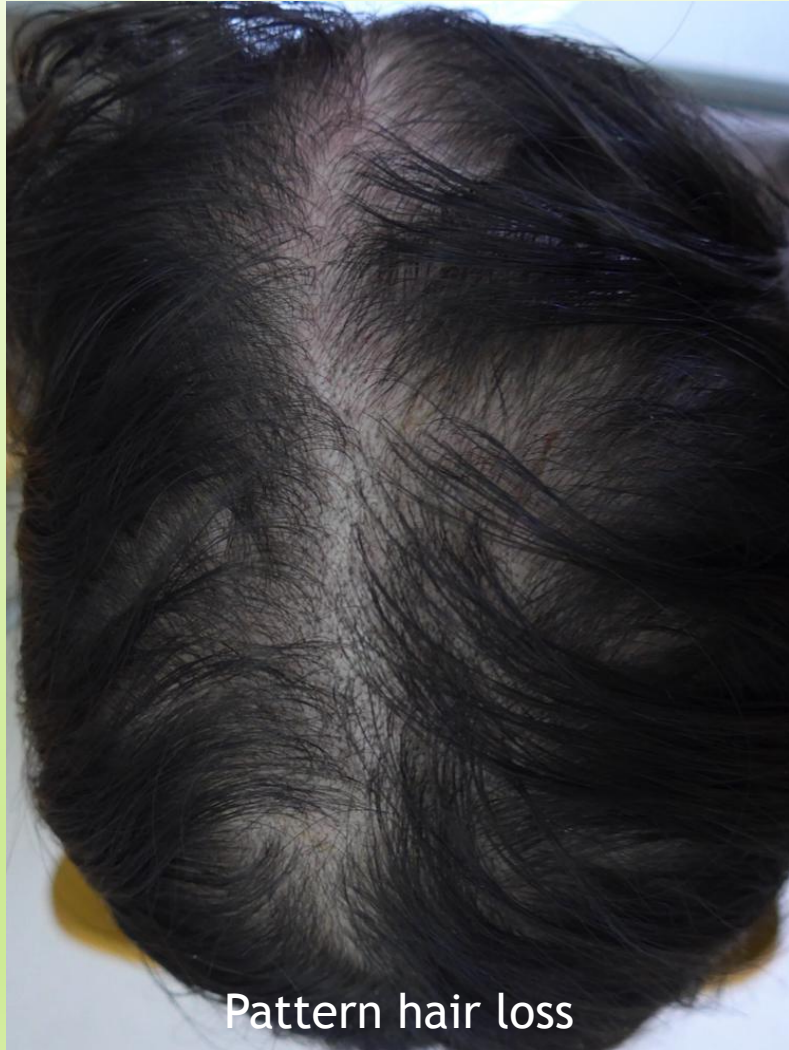

Dramatic
Catagen/telogen
Shift
CT hair $\geq 50\%$

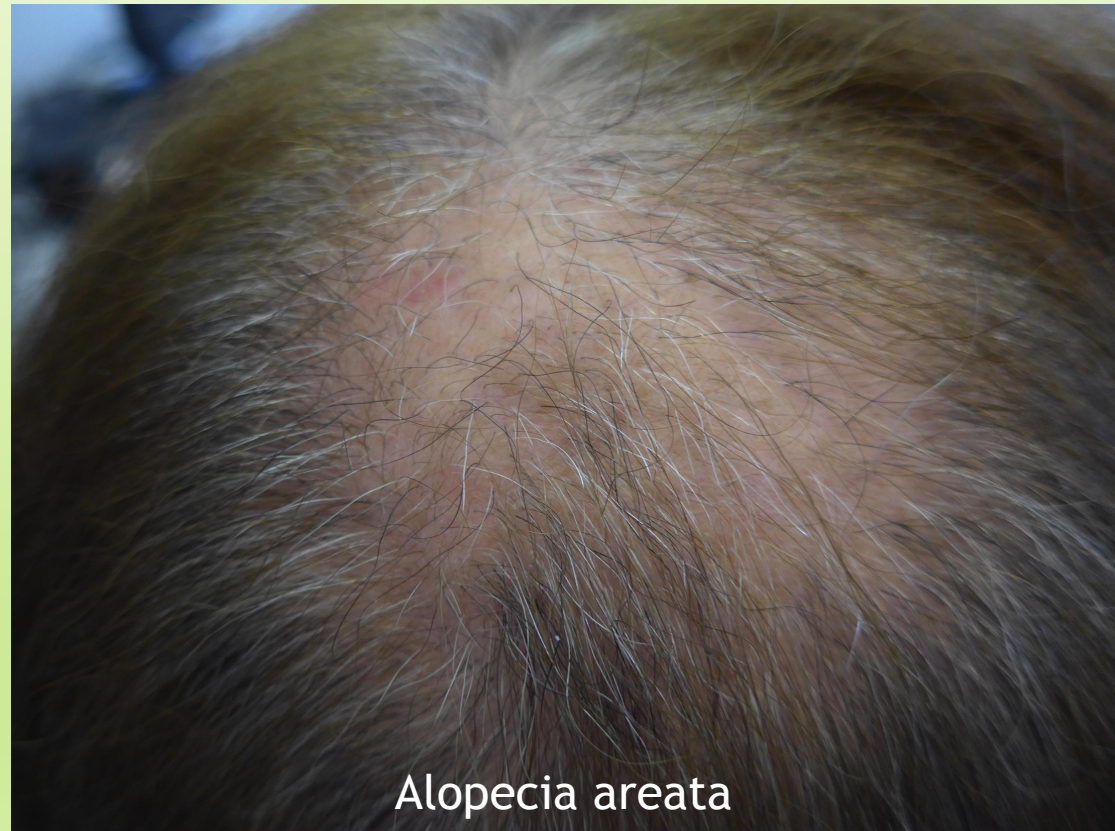
Alopecia areata





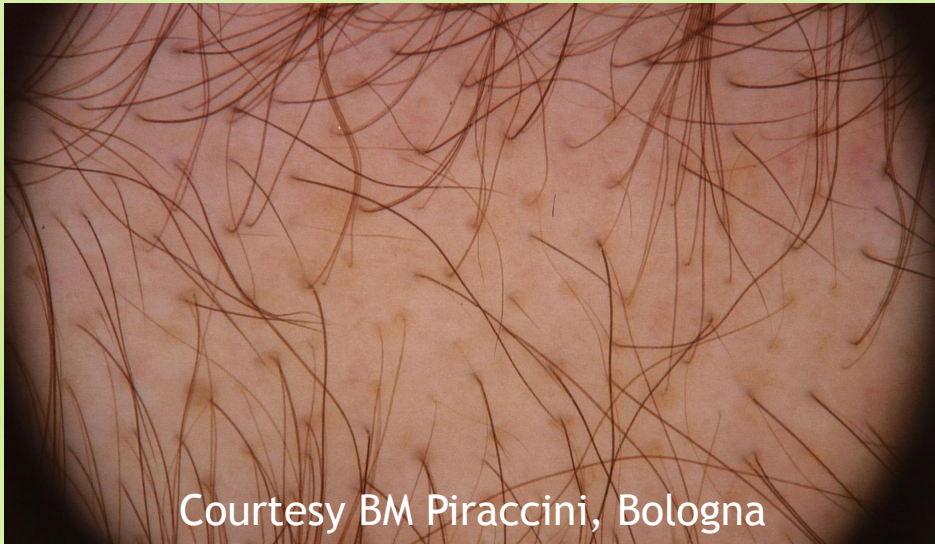
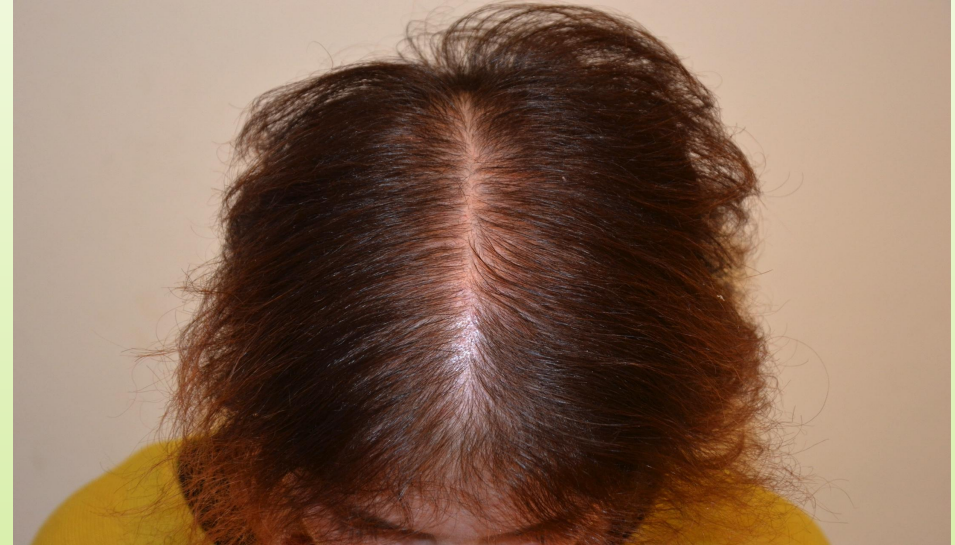
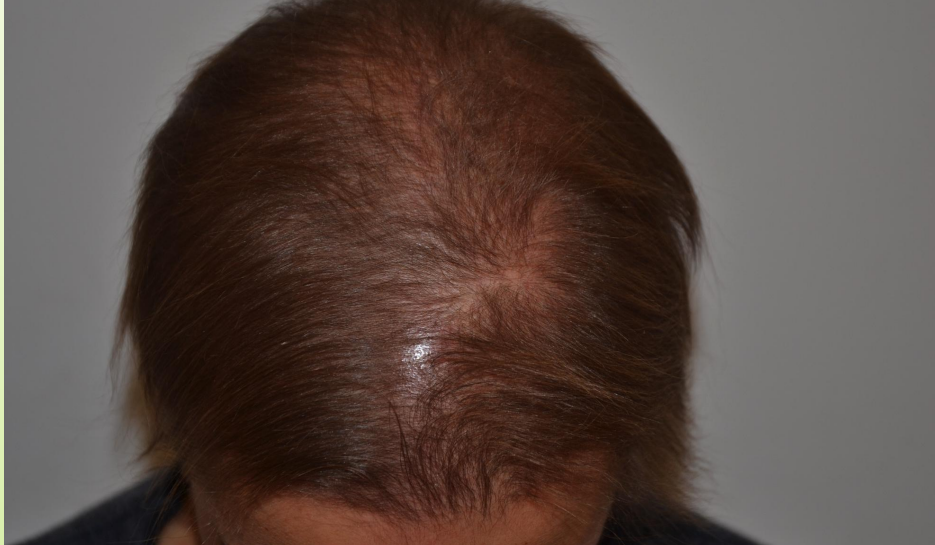
Pattern hair loss

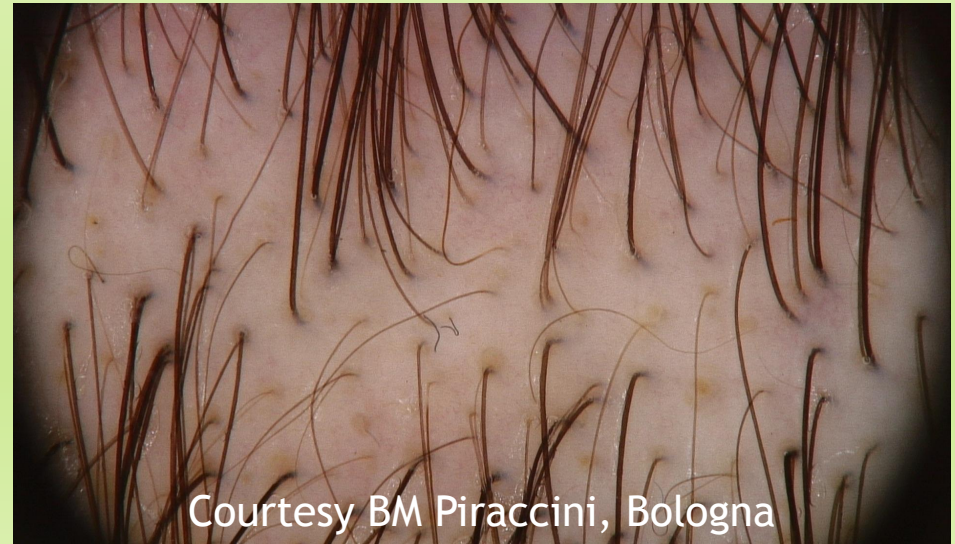

Alopecia areata


Alopecia areata incognita



Courtesy BM Piraccini, Bologna



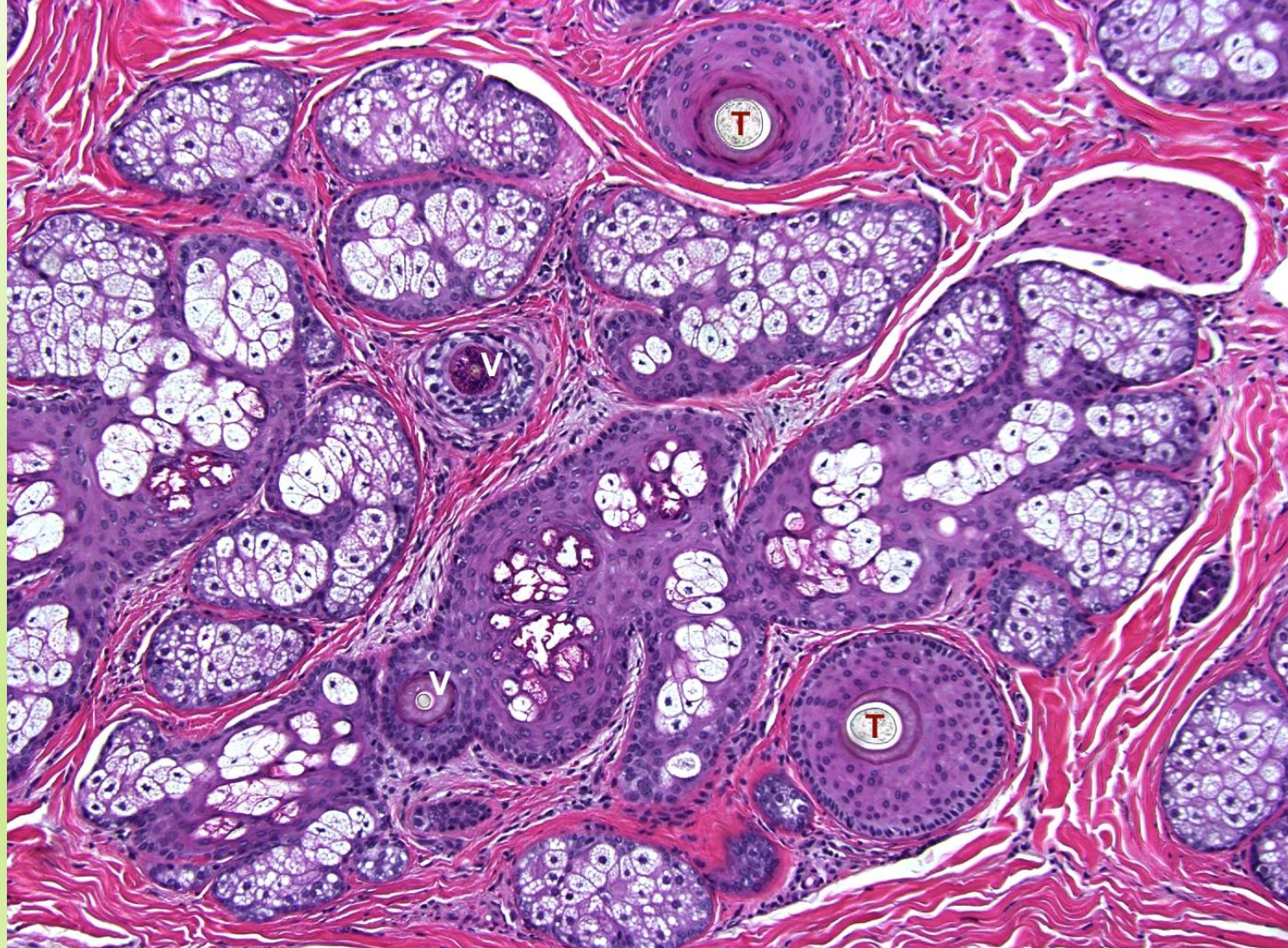
Courtesy BM Piraccini, Bologna



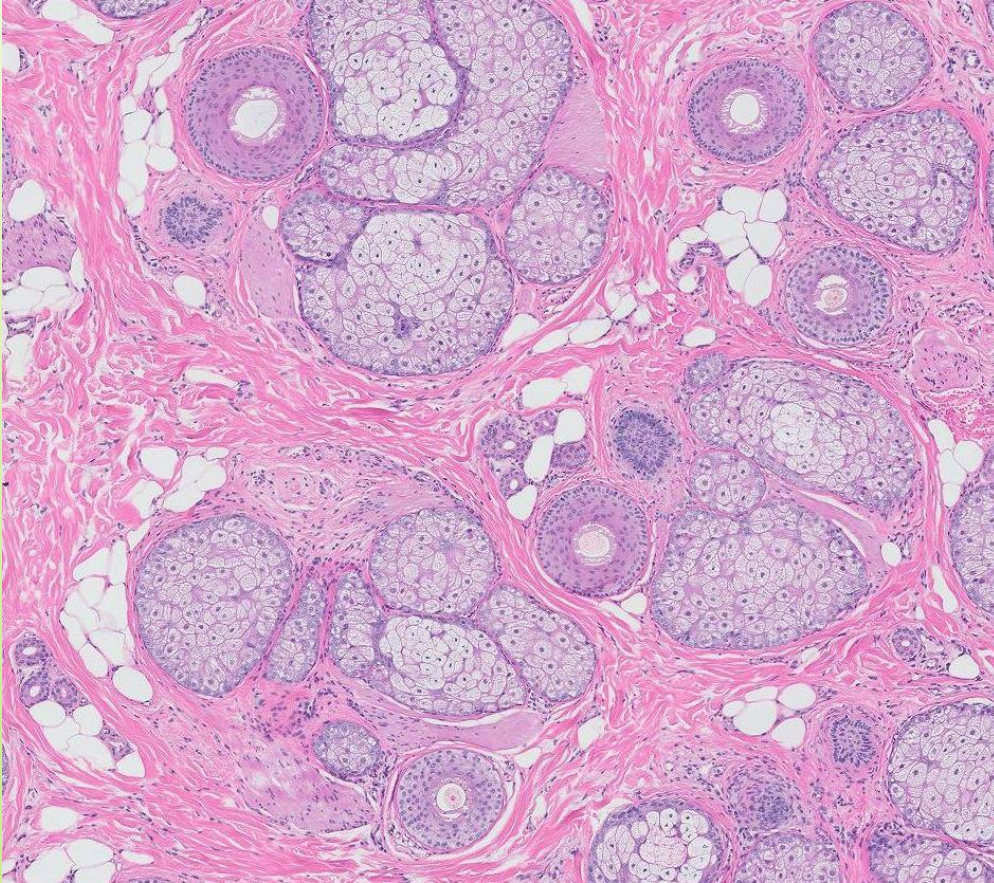
Pattern hair
loss
Alopecia
areata

Alopecia
areata-like
pattern

Pattern Hair Loss (Androgenetic)



Pattern Hair Loss (Androgenetic)



1. T:V ratio
 - 1:1 - 1:3 if <50y
 - Or 1.5:1 - 1:3 if >50y

AND

1. T:V ratio
2. CT hair 10-30%

AND

3. No peribulbar lymphocytic infiltrate

	Pattern hair loss (androgenetic)	Alopecia areata	Chronic telogen effluvium
Terminal/Vellus hair ratio	Decreased	Decreased	Normal
% catagen and telogen hair	Increased	Increased	Increased

1. Elston DM, Ferringer T, Dalton S, Fillman E, Tyler W. A comparison of vertical versus transverse sections in the evaluation of alopecia biopsy specimens. *Journal of American Academy of Dermatology* 2005; 53: 267.
2. Wohltmann WE, Sperling LC. Histopathologic diagnosis of multifactorial alopecia. *Journal of Cutaneous Pathology* 2016; 43: 483.

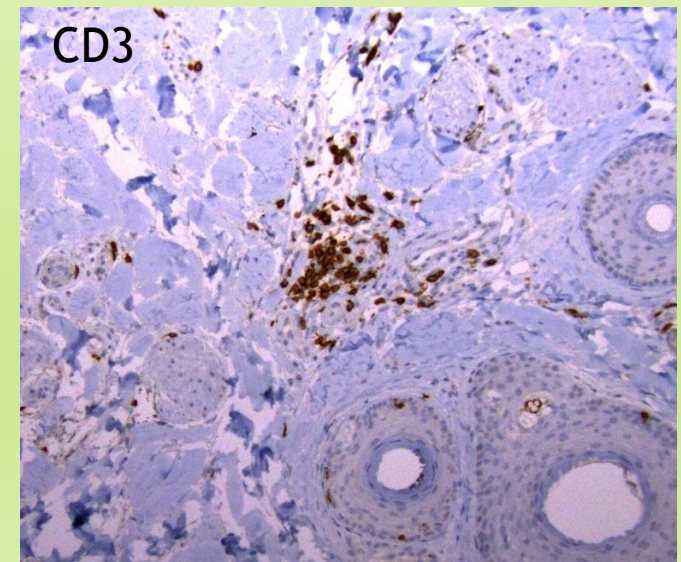
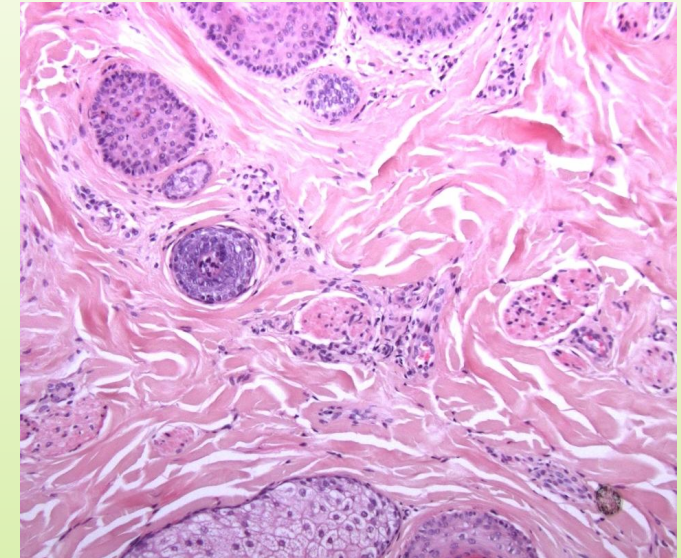
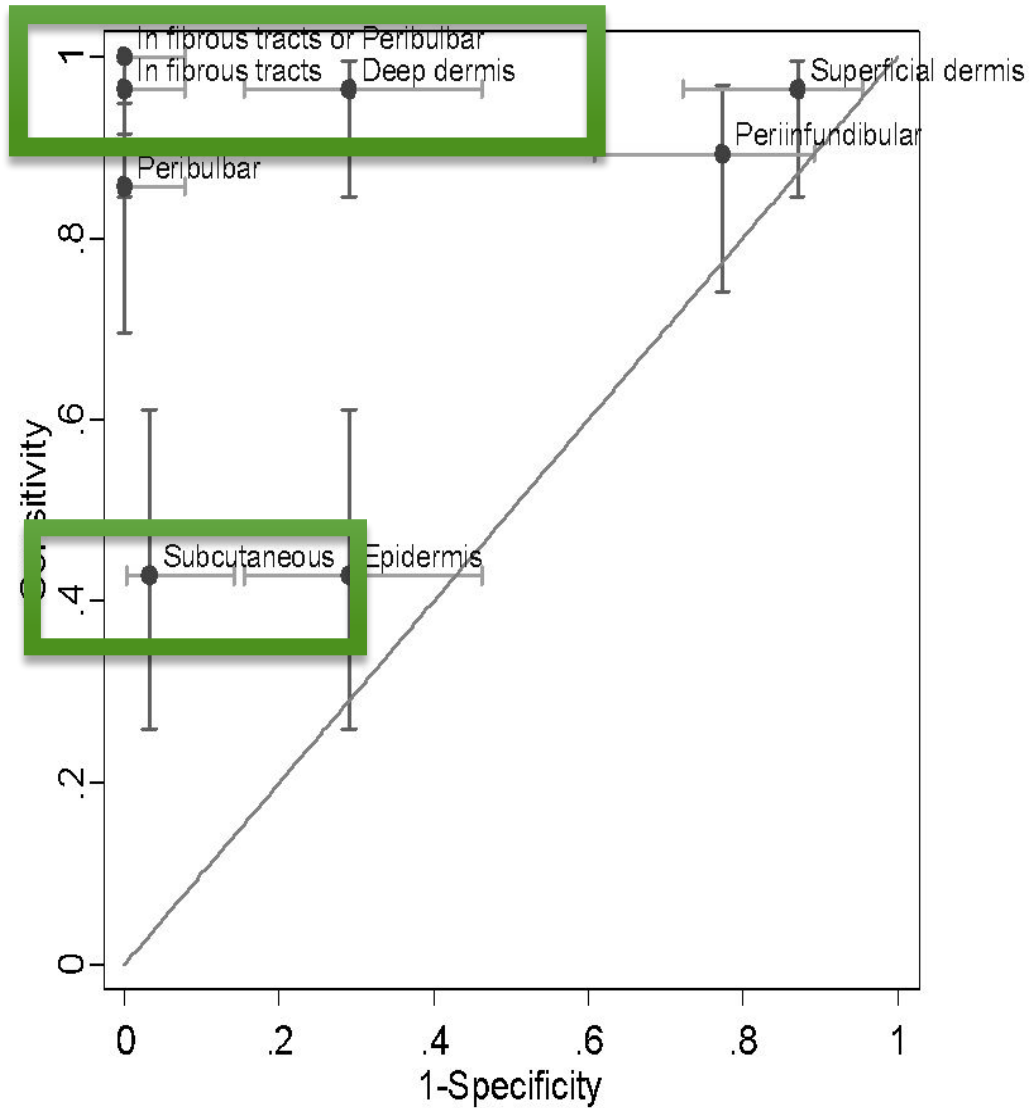
Kolivras A., Thompson C.

Distinguishing diffuse alopecia areata from
pattern hair loss using CD3+ T cells.

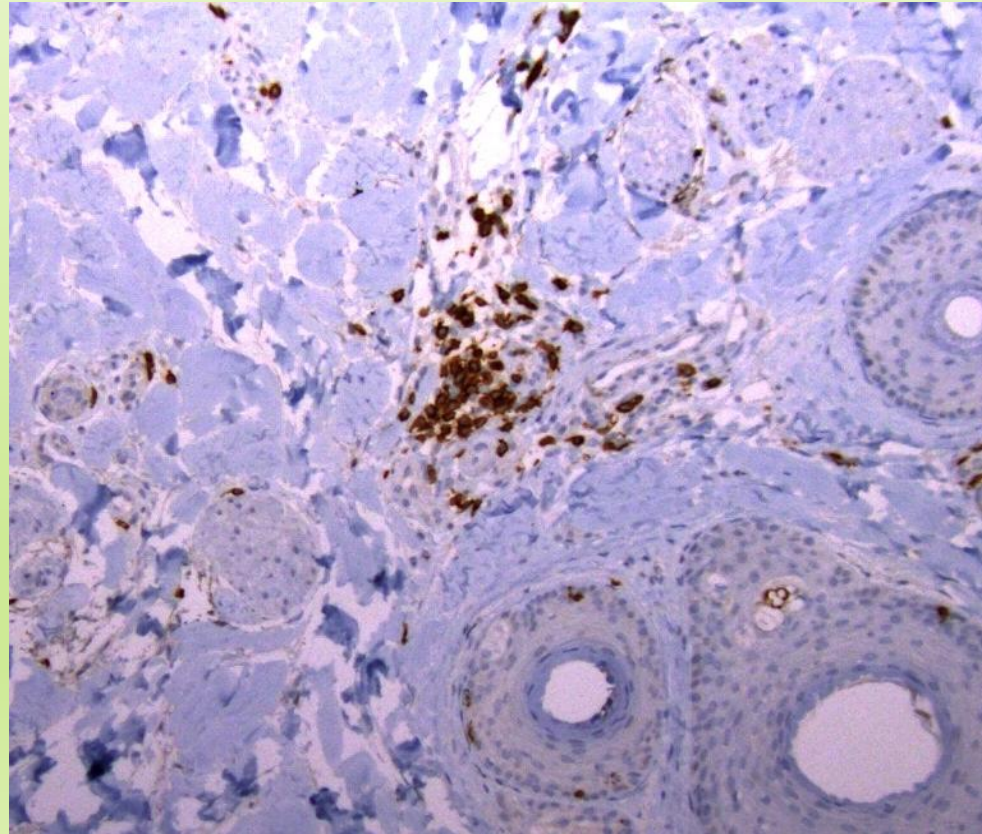
*Journal of American Academy of
Dermatology* 2016; 74: 937-44.



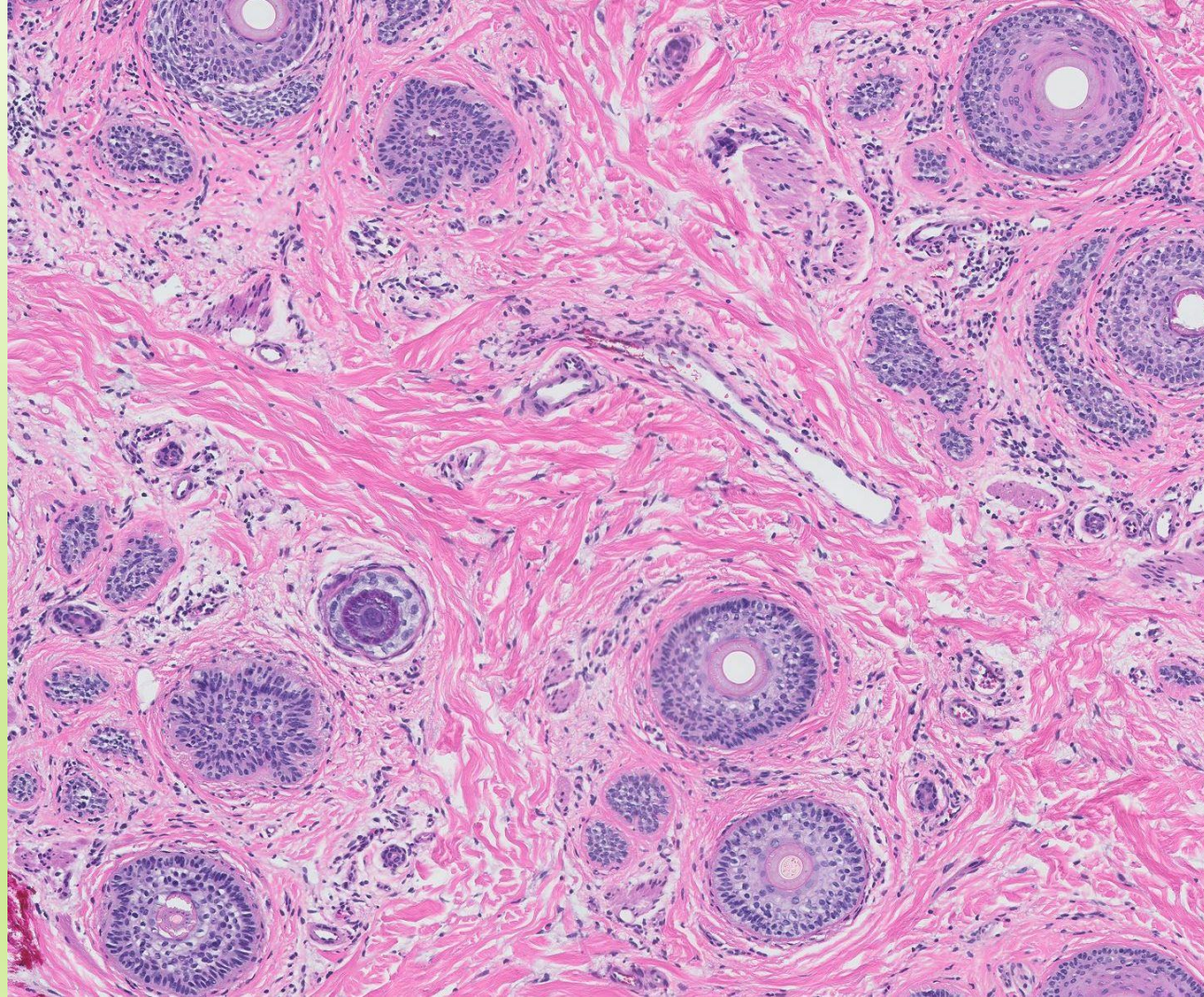
Alopecia areata

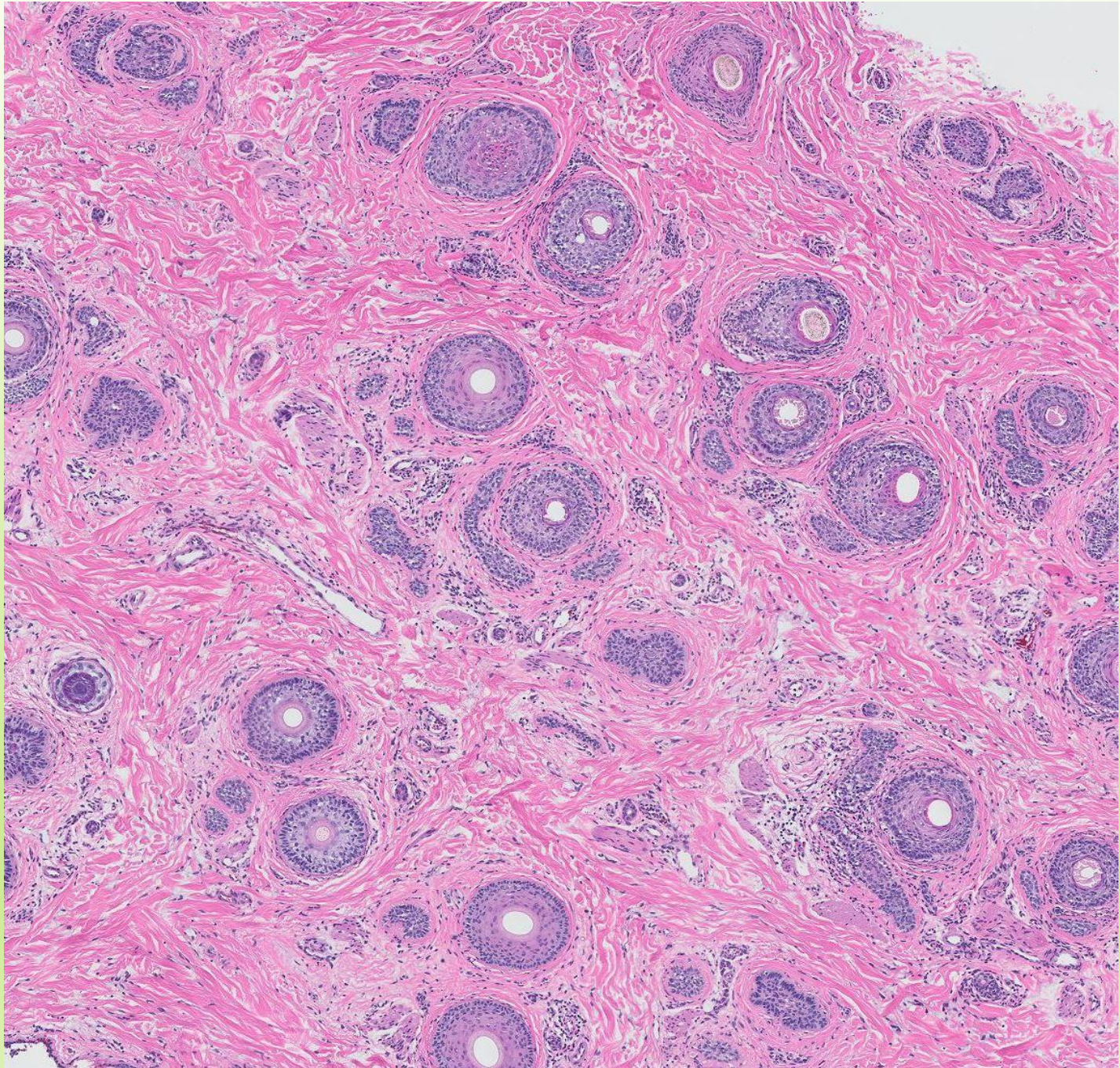


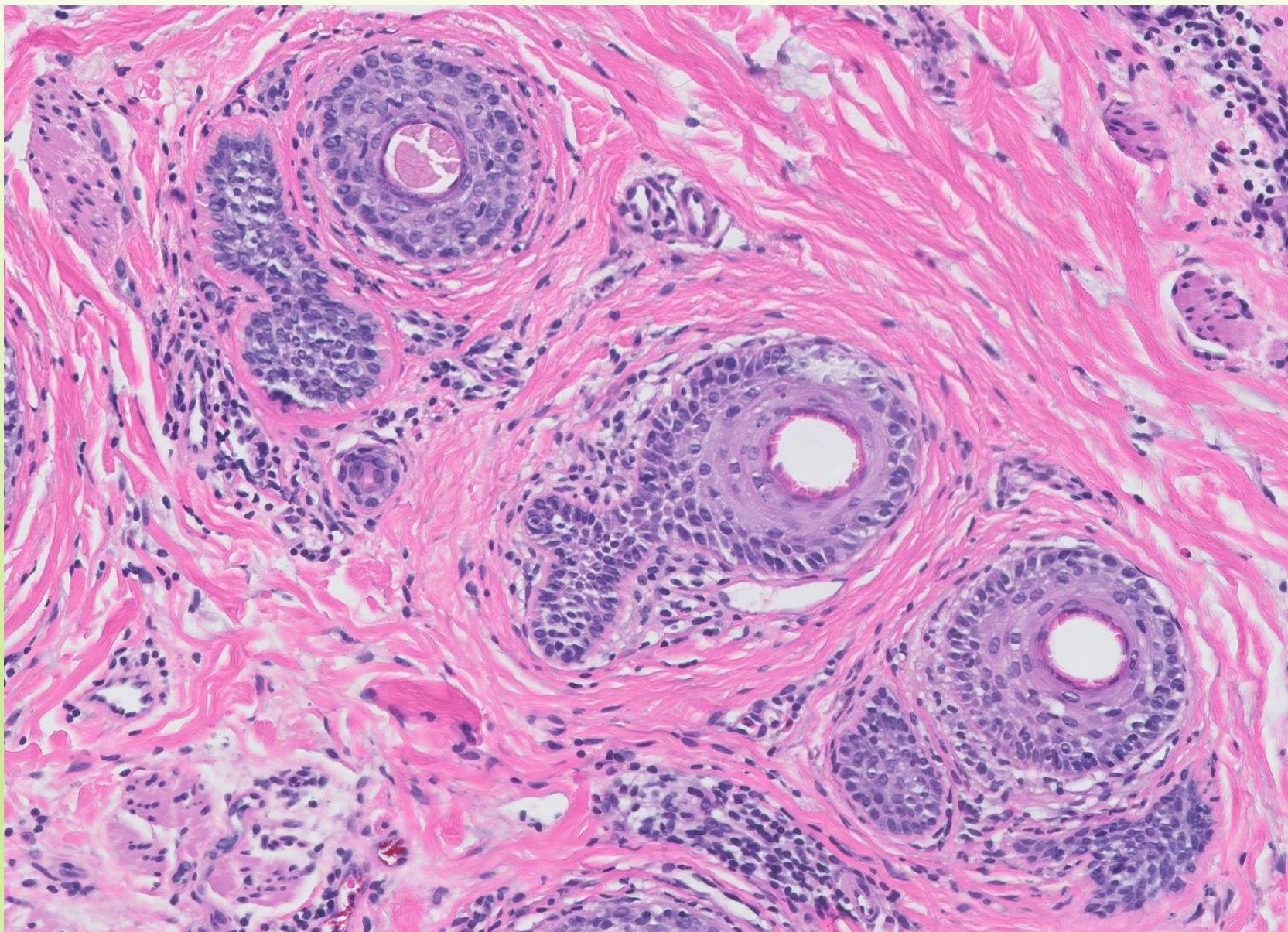
**CD3+ T-lymphocytes within empty
fibrous follicular tracts favors a
diagnosis of Alopecia areata**

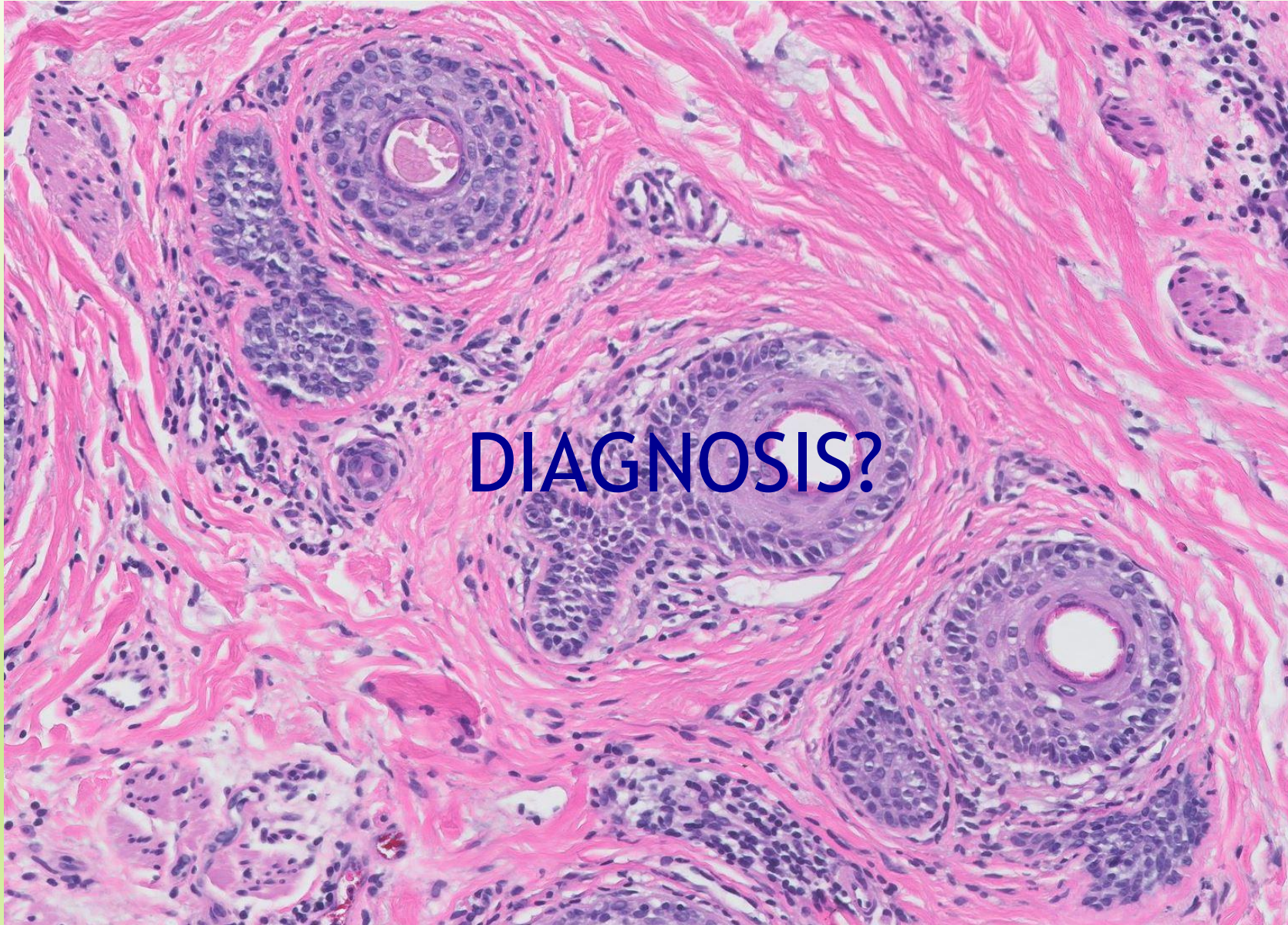


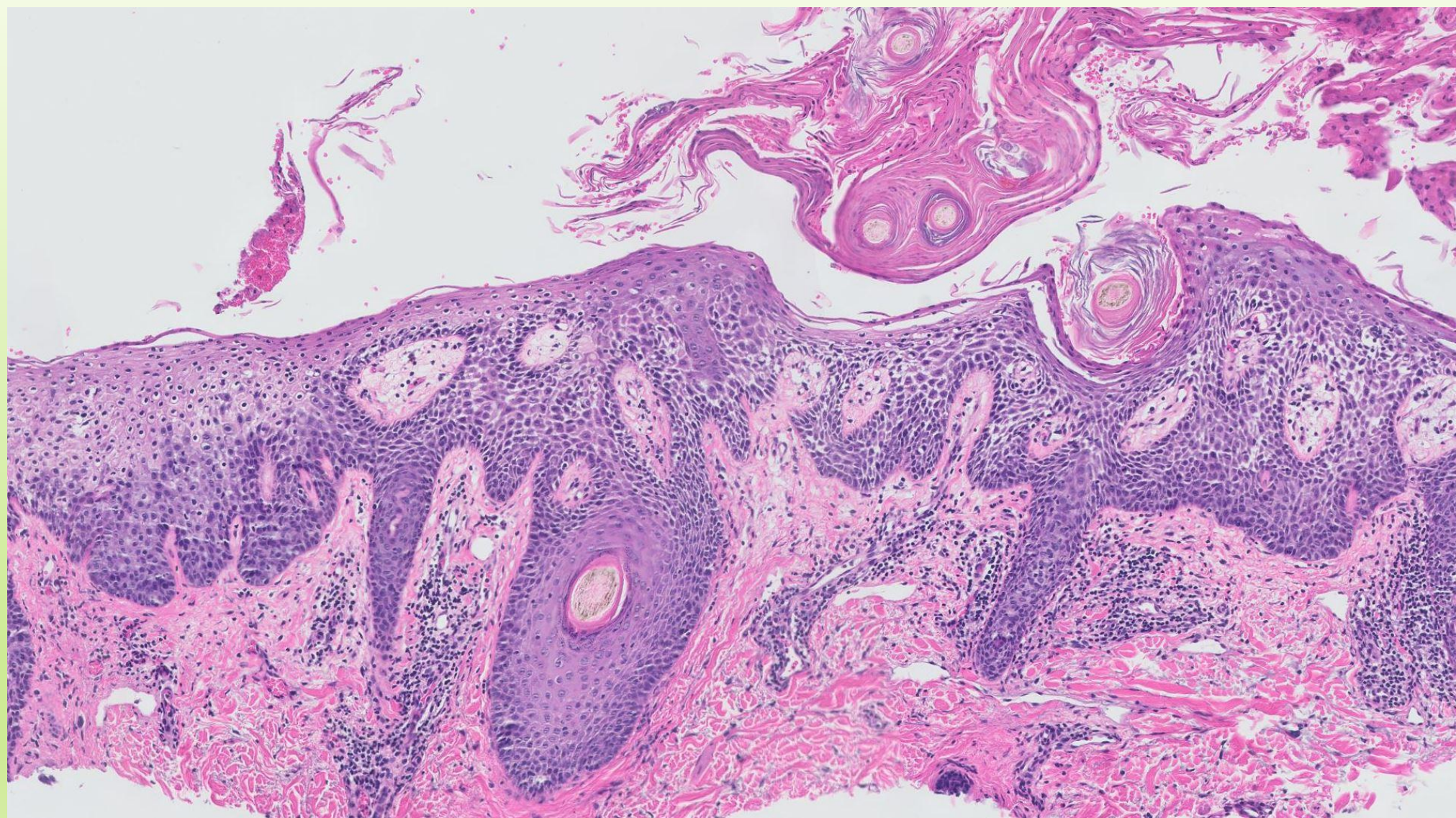
What is your diagnosis?

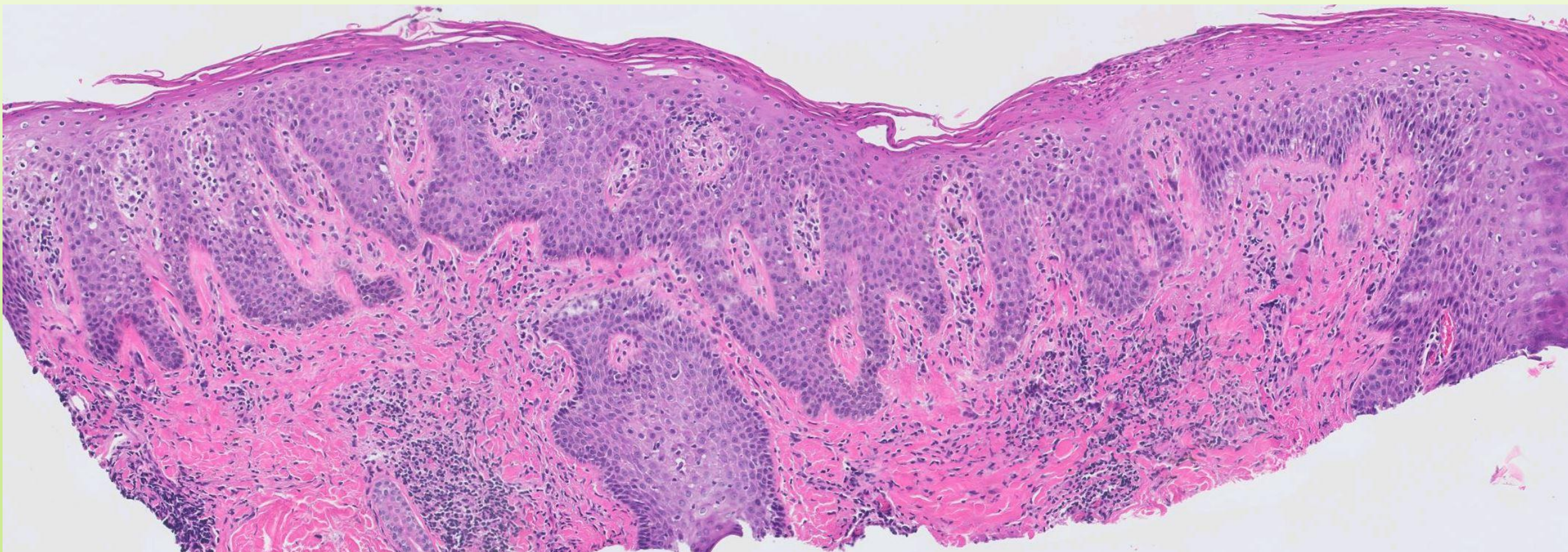




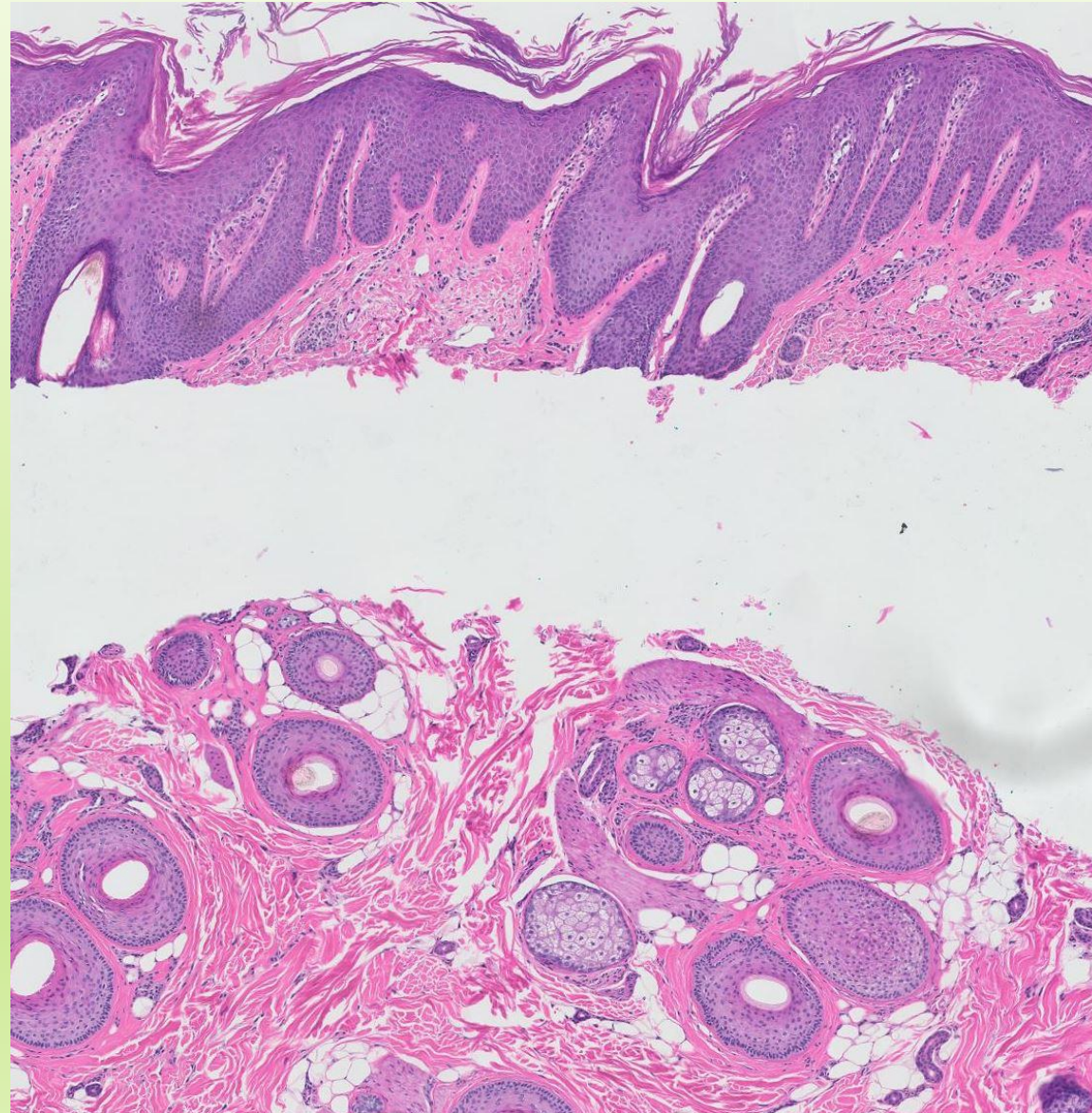




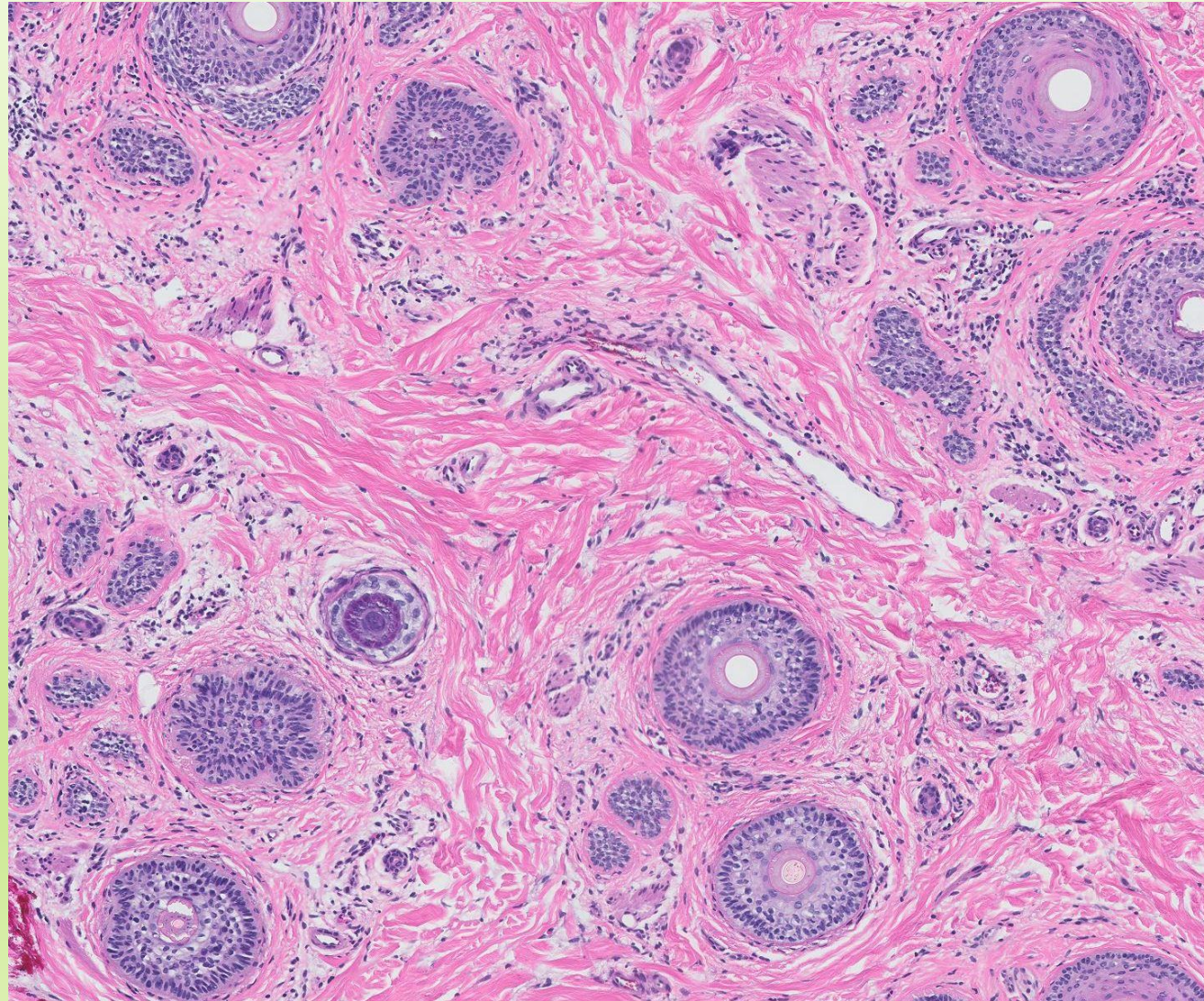




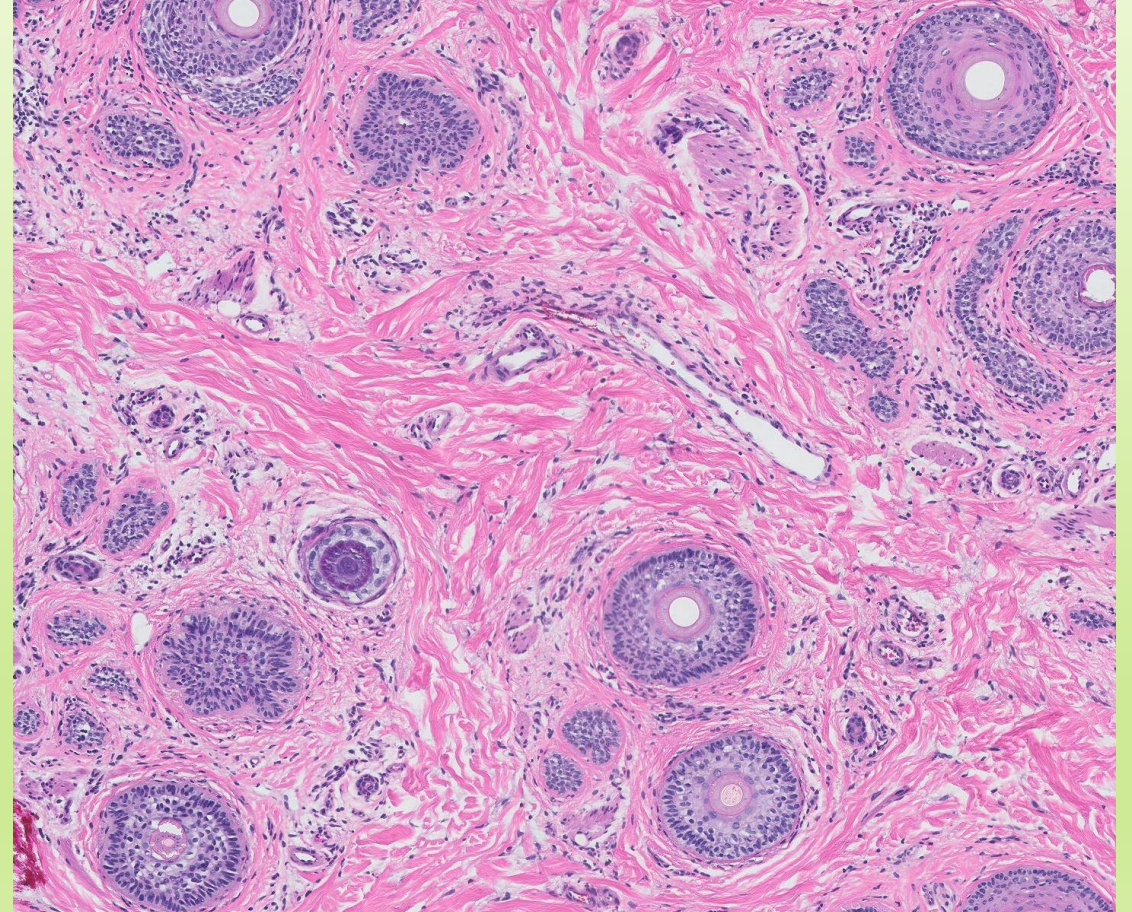
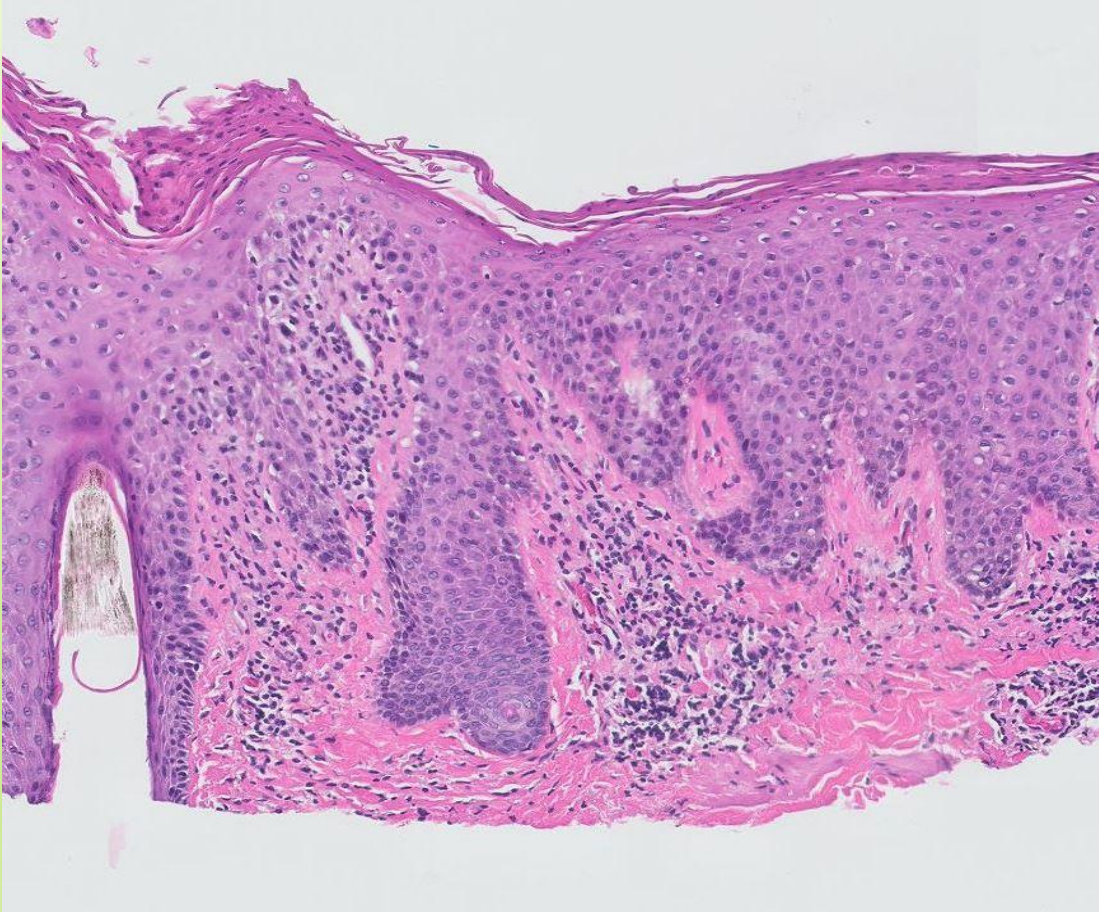
Psoriatic Alopecia



Alopecia Areata-like Pattern



TNF-alpha inhibitor-associated alopecia



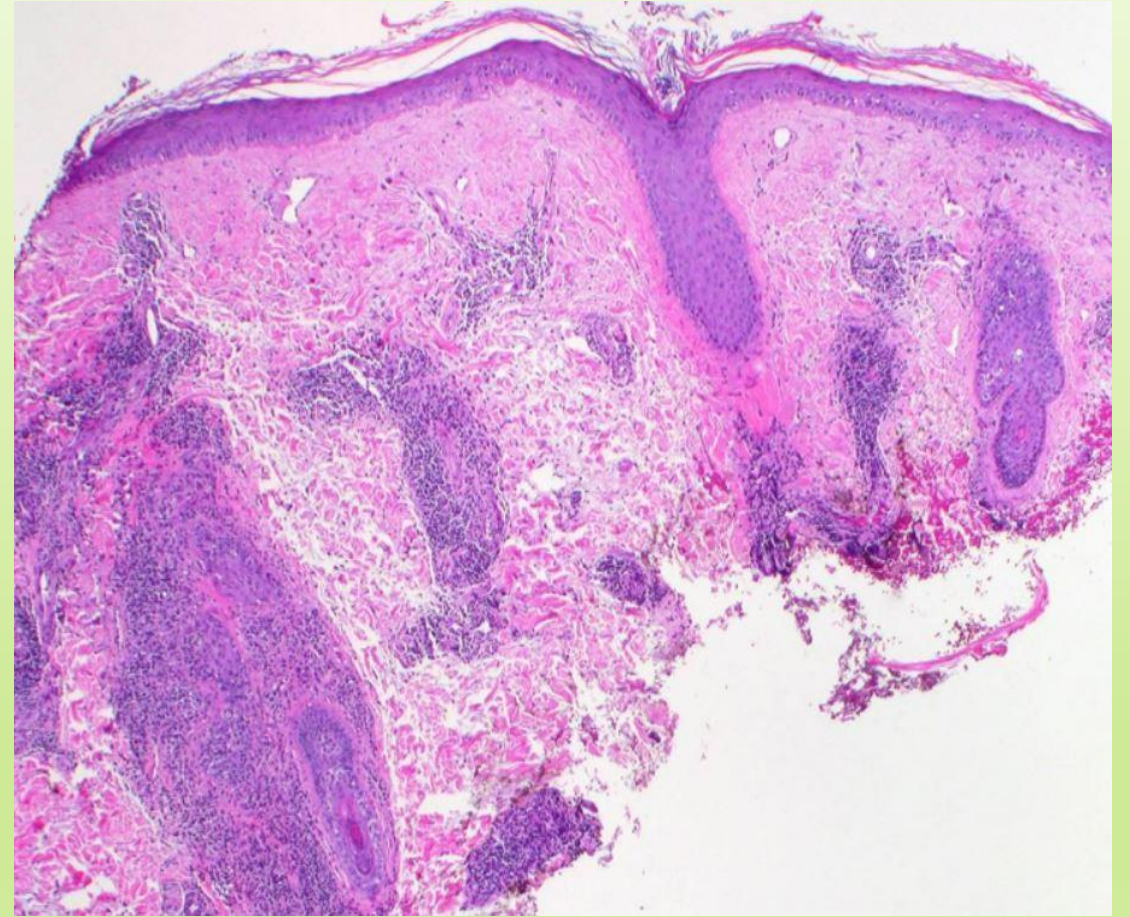
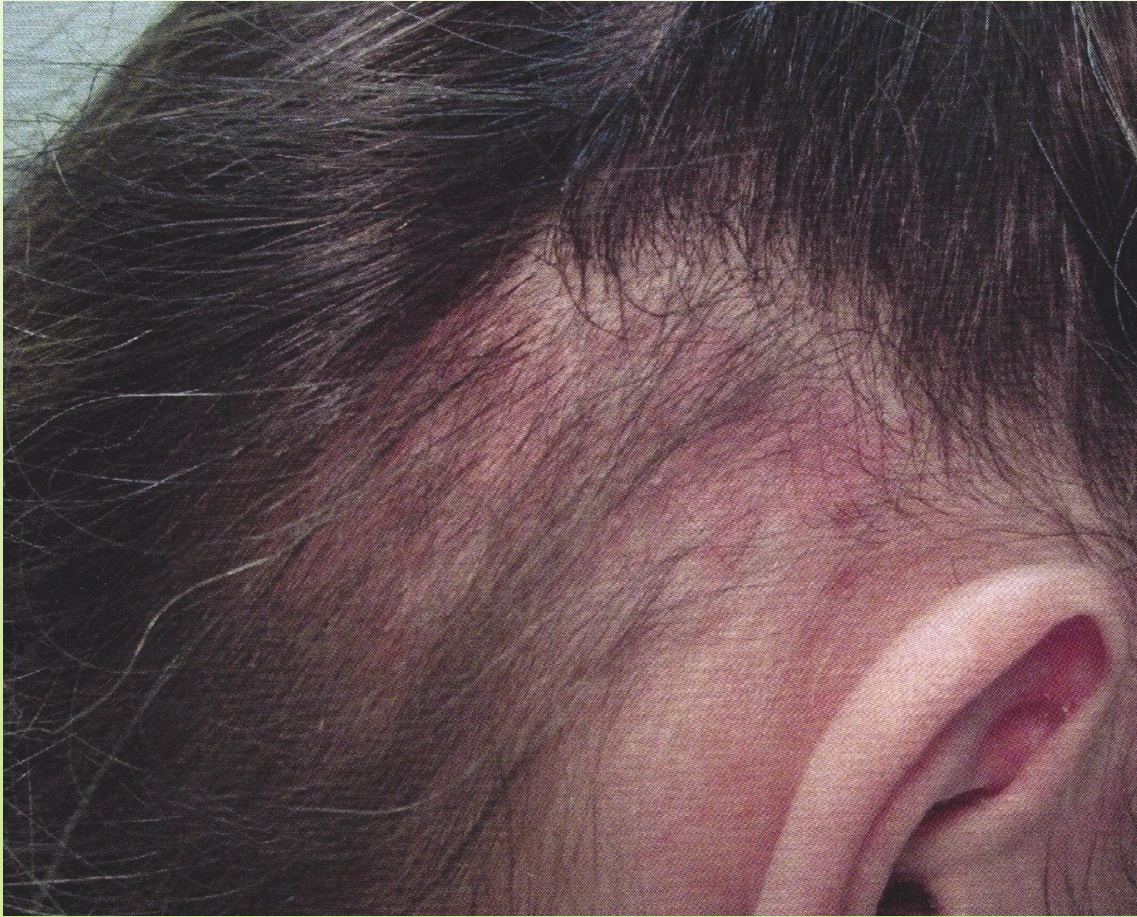
TNF-alpha inhibitor-associated alopecia

- ▶ Very close histologically to psoriatic alopecia
- ▶ TNF-alpha inhibitors may also induced alopecia areata

Doyle LA et al. Psoriatic alopecia/alopecia areata-like reactions secondary to anti-tumor necrosis factor- α therapy: a novel cause of noncicatricial alopecia. Am J Dermatopathol. 2011 Apr;33(2):161-6.

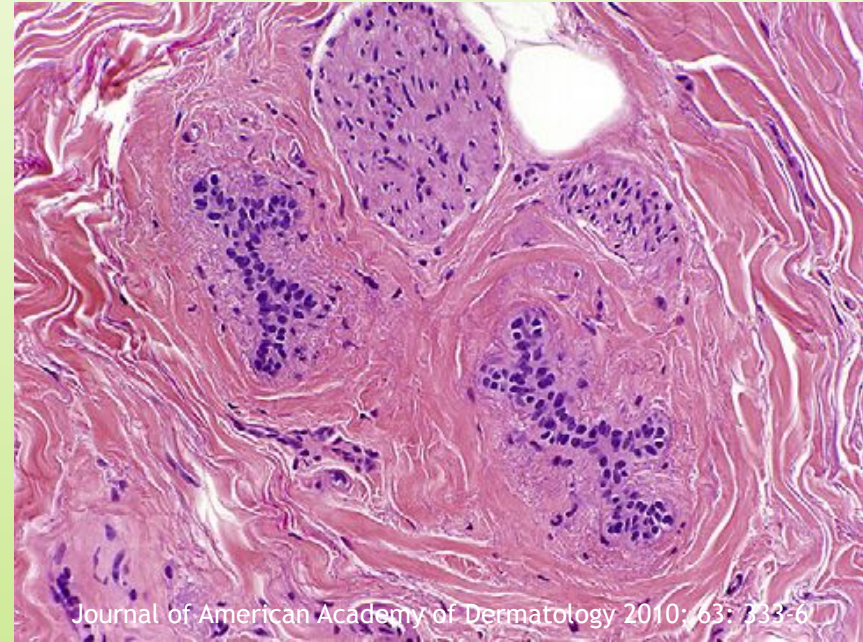
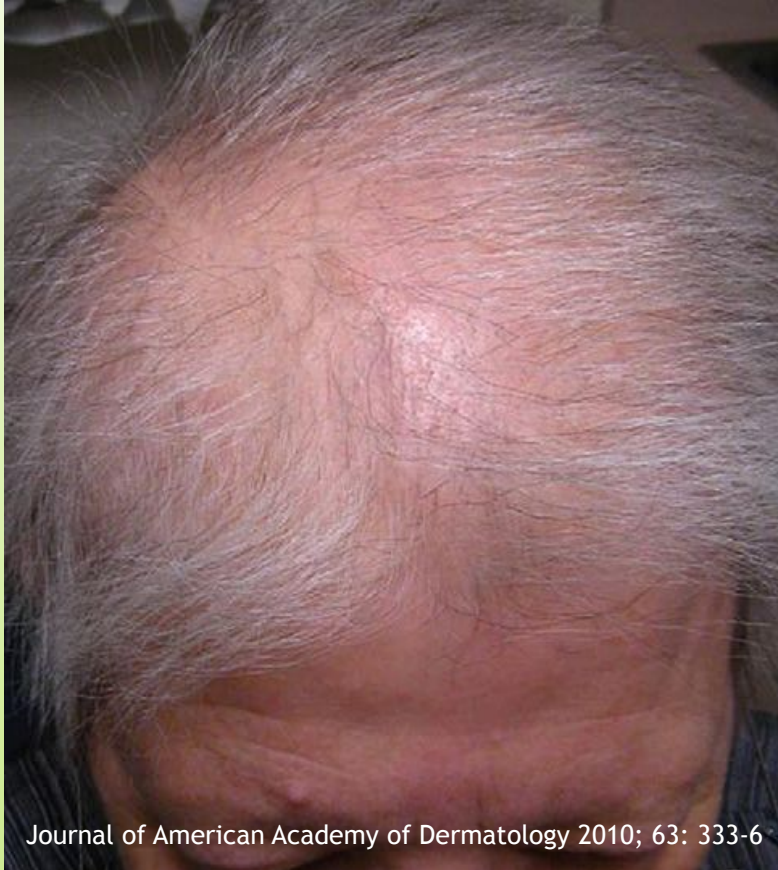
Systemic lupus erythematosus

Non-scarring alopecia



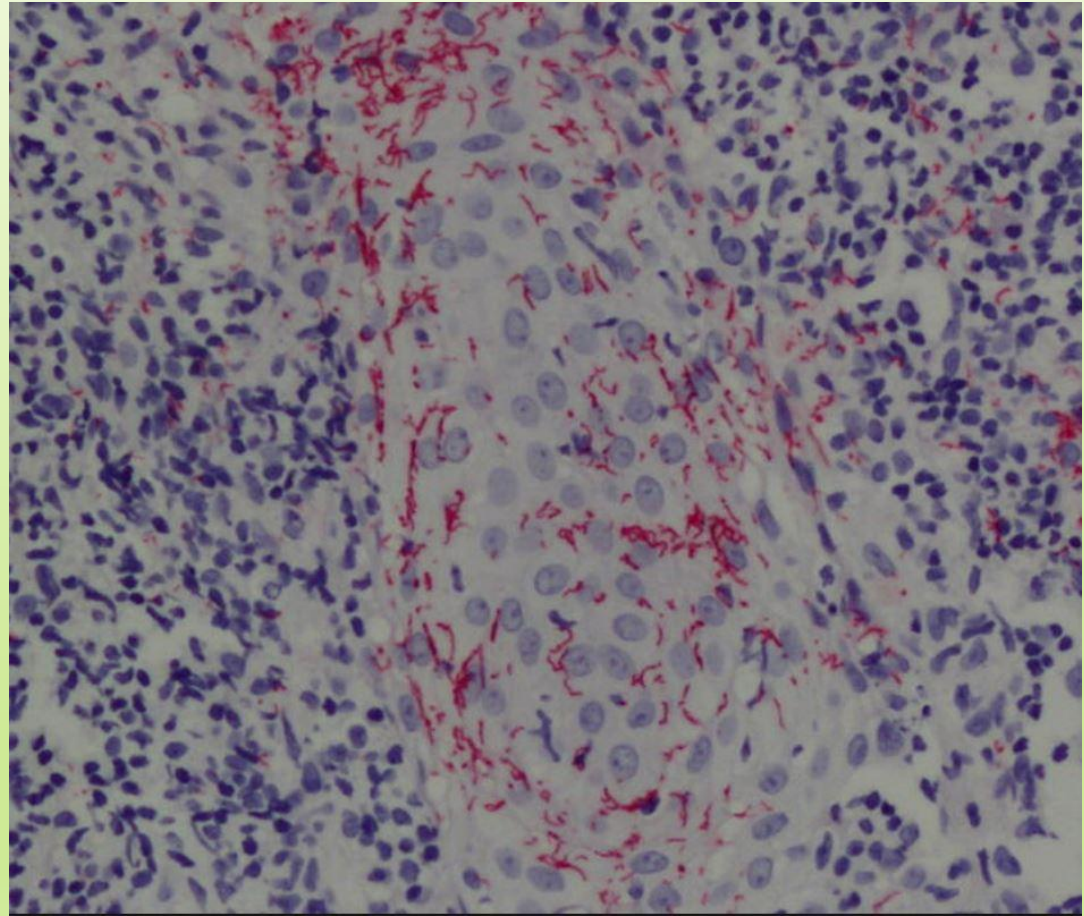
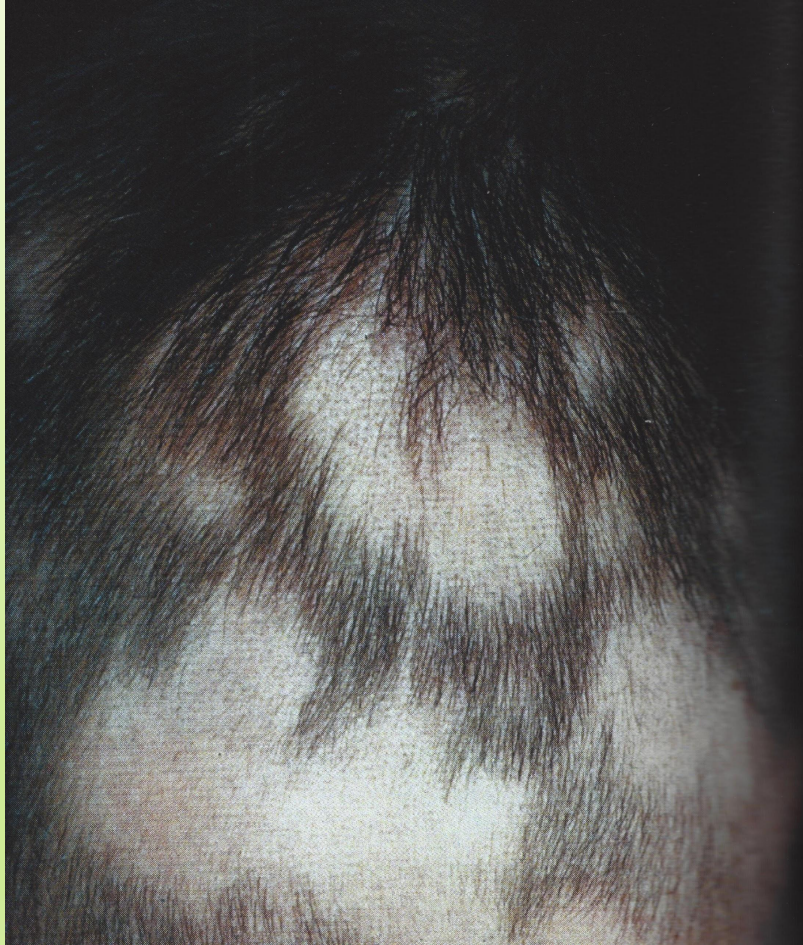
Sperling LC, Cowper SE, Knopp EA. An Atlas of Hair Pathology with Clinical Correlations. 2nd ed. Boca Raton (FL): Taylor and Francis Group, 2012.

Permanent chemotherapy-induced alopecia



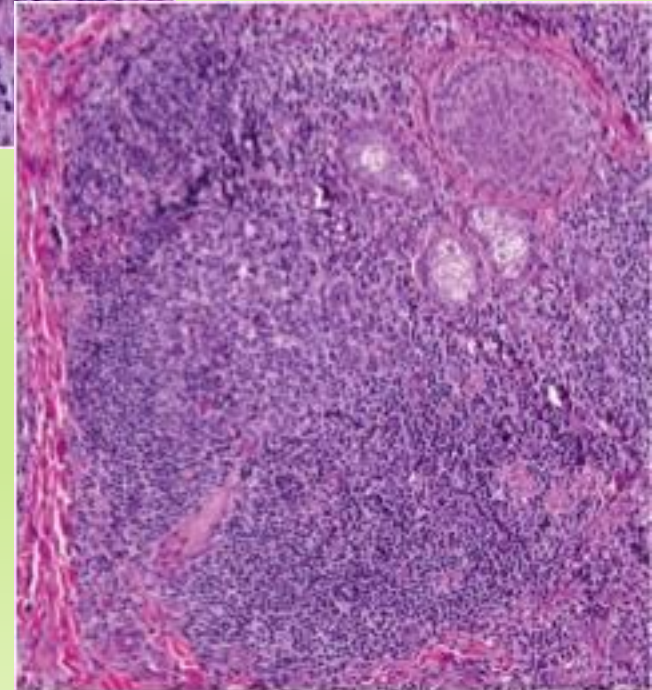
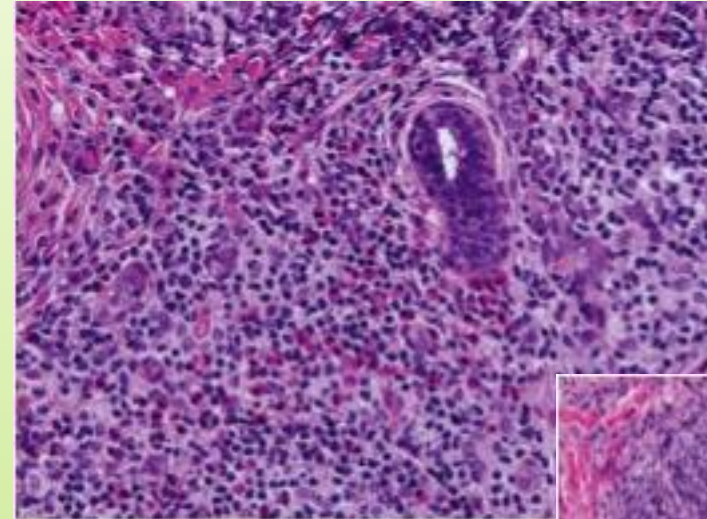
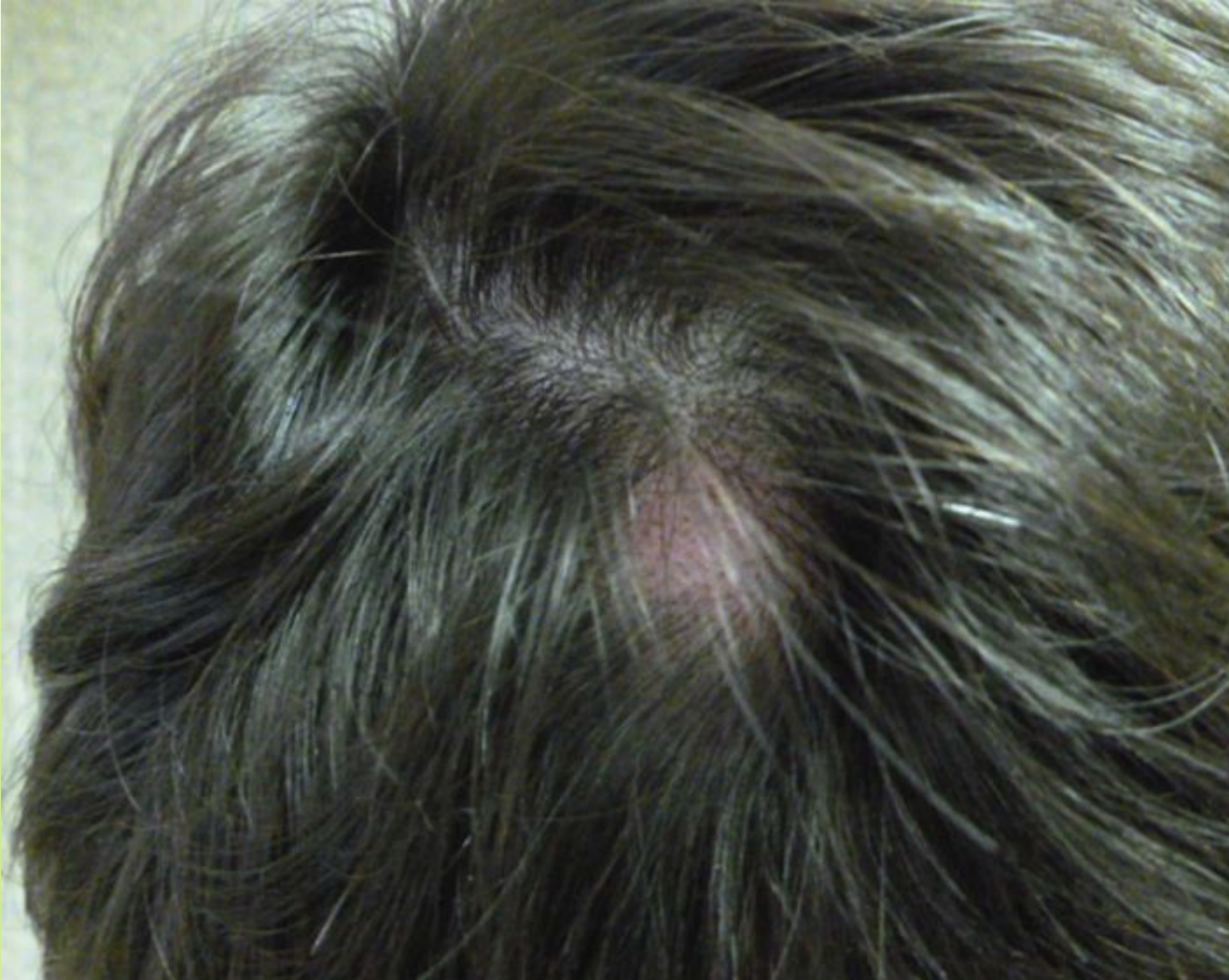1. Miteva M, Misciali C, Fanti PA, Vincenzi C, Romanelli P, Tosti A. Permanent alopecia after systemic chemotherapy: a clinicopathological study of 10 cases. *American Journal of Dermatopathology* 2011; 33: 345.
2. Tallon B, Blanchard E, Goldberg LJ. Permanent chemotherapy-induced alopecia: Case report and review of the literature. *Journal of American Academy of Dermatology* 2010; 63: 333.

Syphilis



Sperling LC, Cowper SE, Knopp EA. An Atlas of Hair Pathology with Clinical Correlations. 2nd ed. Boca Raton (FL): Taylor and Francis Group, 2012.

Tick-bite Alopecia



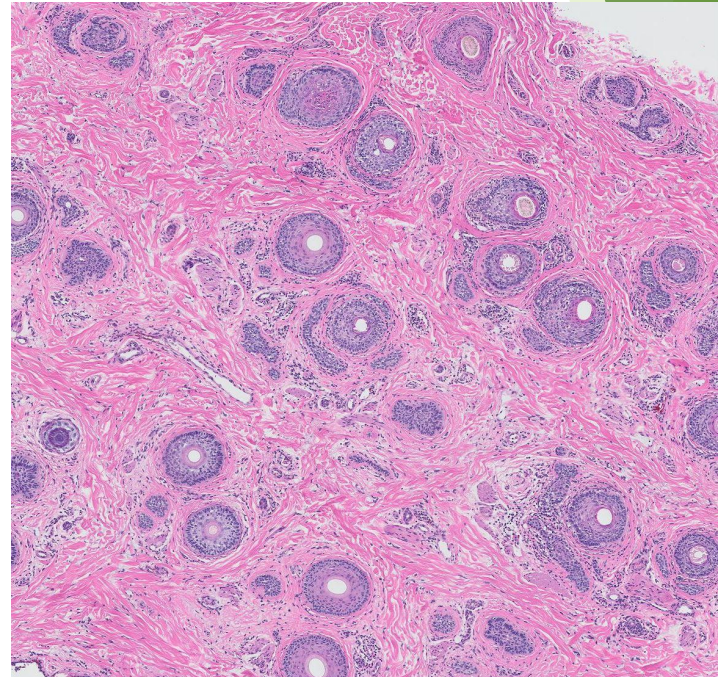
Alopecia Areata-like Pattern

1. Check the epidermis
2. Antinuclear antibodies and syphilis serology
3. Syphilis immunostain

Alopecia Areata-like Pattern

Marked miniaturization with reduced anagen phase:

- ▶ Alopecia areata
- ▶ Psoriatic alopecia
- ▶ TNF-alpha inhibitor induced psoriasiform alopecia
- ▶ Syphilitic alopecia
- ▶ Non-scarring alopecia of systemic lupus erythematosus
- ▶ Tick-bite alopecia



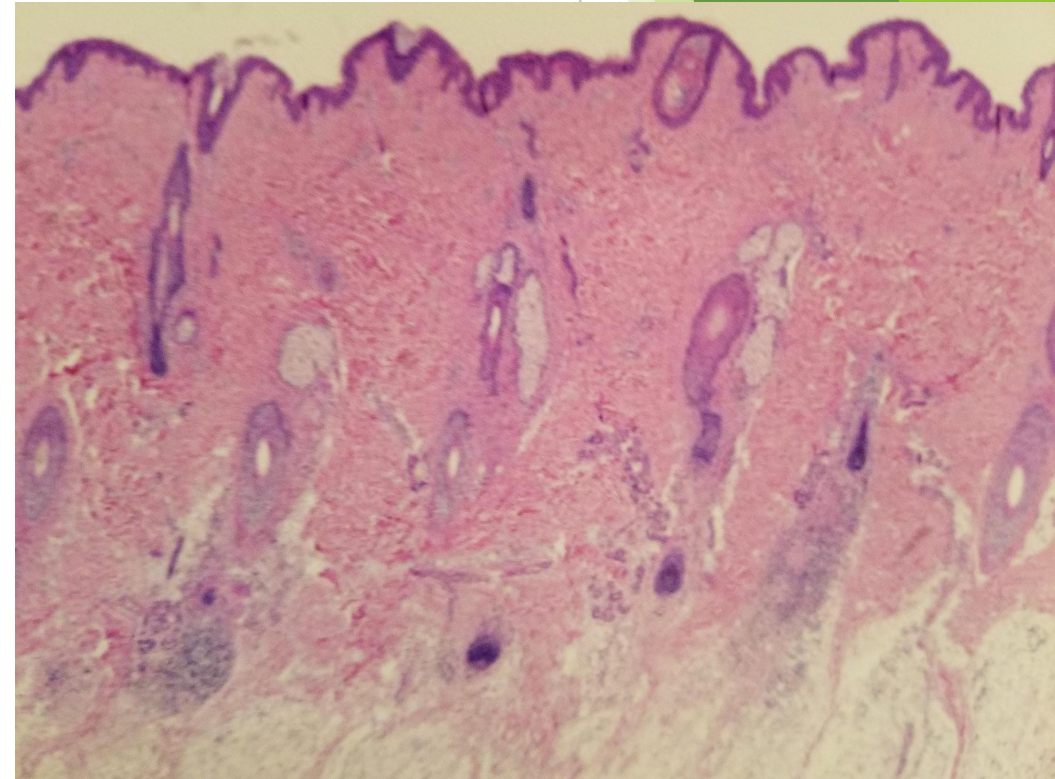
P-203

A case of centrifugal lipodystrophic alopecia

Kazutoshi HARADA¹⁾, Tatsuo MAEDA¹⁾,
Masaki UCHIYAMA¹⁾, Ryokichi IRISAWA¹⁾, Kikyo GO²⁾,
Ryoji TSUBOI¹⁾

1) Tokyo Medical University, Japan

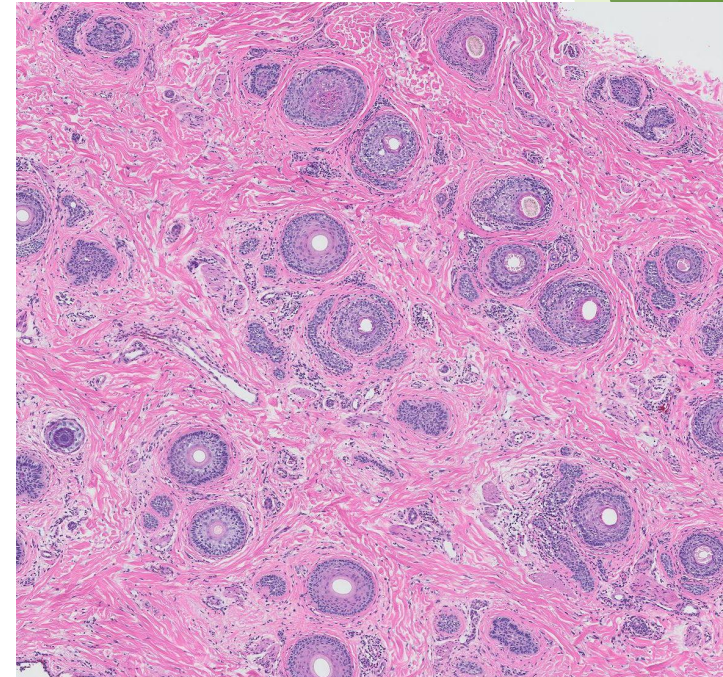
2) Dermatology Go Clinic



Alopecia Areata-like Pattern

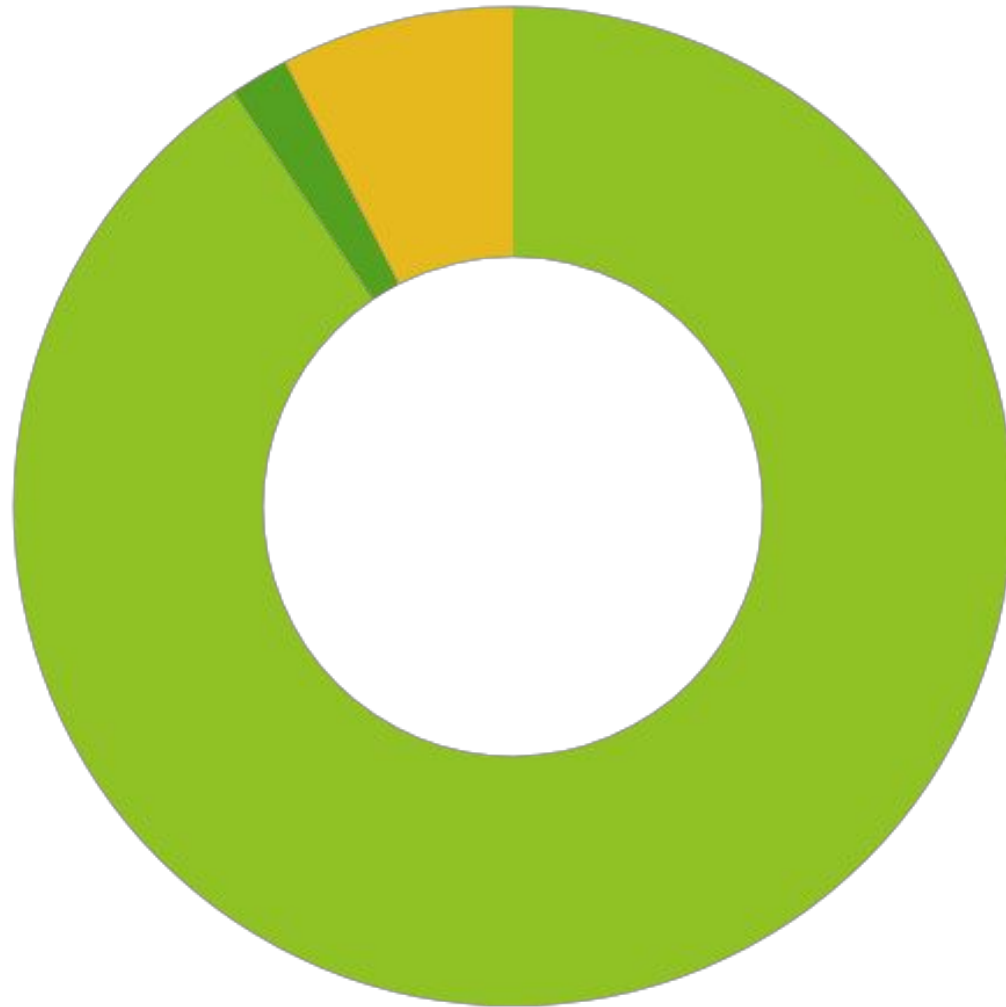
Marked miniaturization with reduced anagen phase:

- ▶ Alopecia areata
- ▶ Psoriatic alopecia
- ▶ TNF-alpha inhibitor induced psoriasiform alopecia
- ▶ Syphilitic alopecia
- ▶ Non-scarring alopecia of systemic lupus erythematosus
- ▶ Tick-bite alopecia
- ▶ **Centrifugal lipodystrophic alopecia of Harada**



**Why do such different
entities share a common
pattern?**

Terminal hair

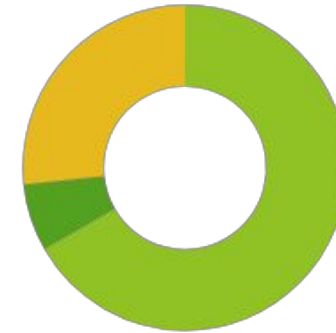

■ Anagen ■ Catagen ■ Telogen

Miniaturization

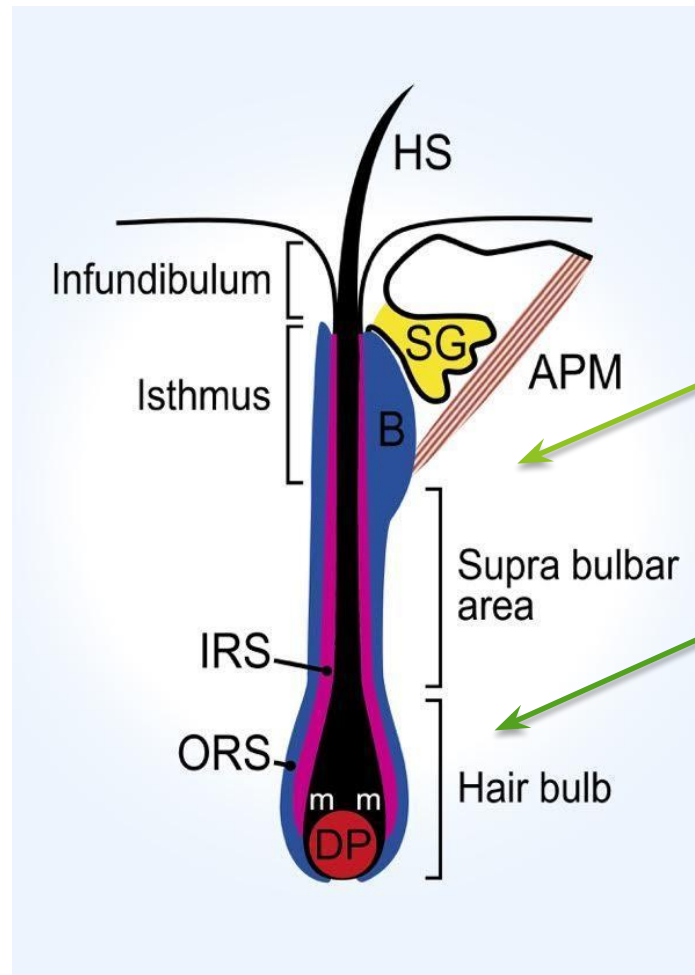


Vellus hair



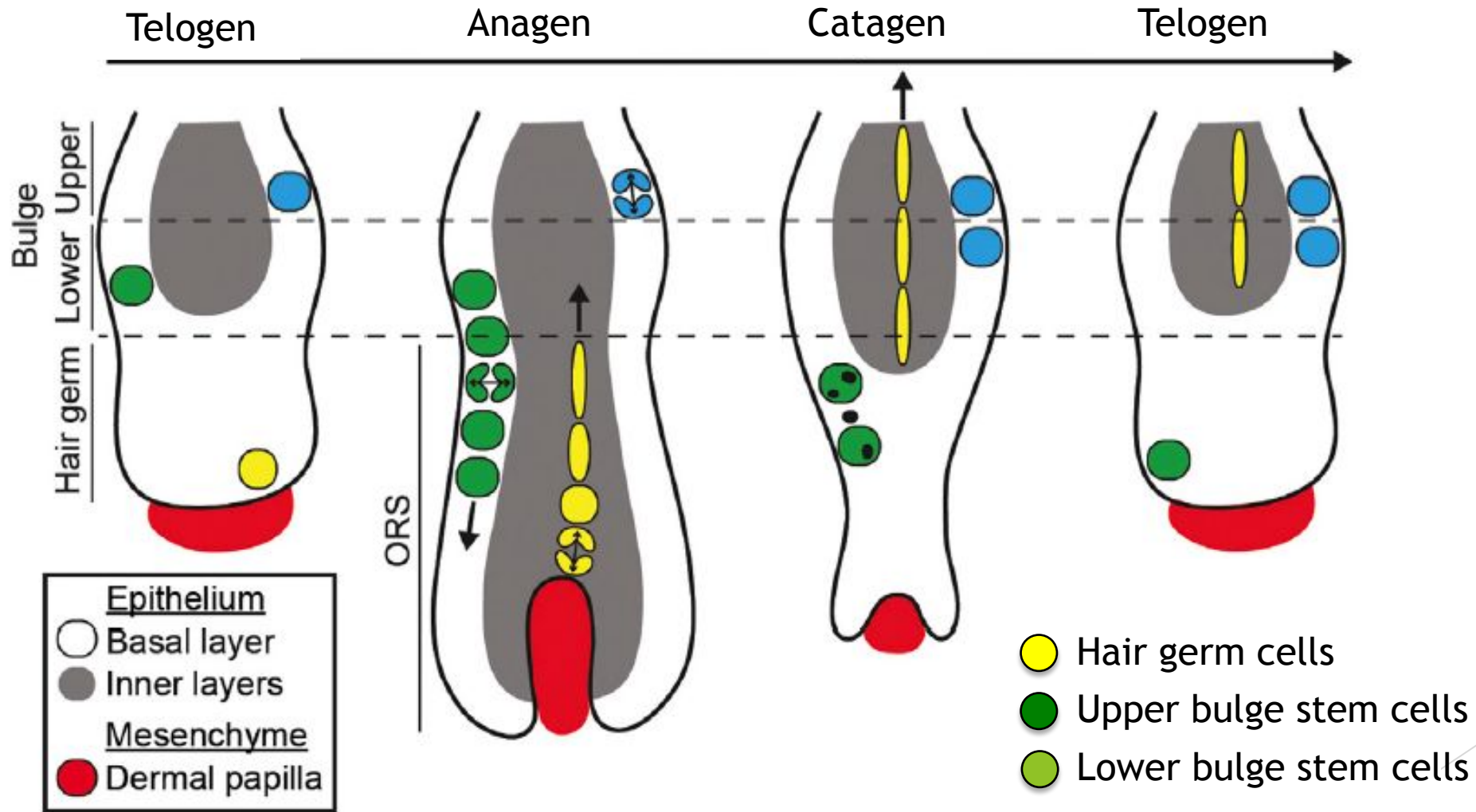
■ Anagen ■ Catagen ■ Telogen

Coexistence of two functionally distinct stem cells

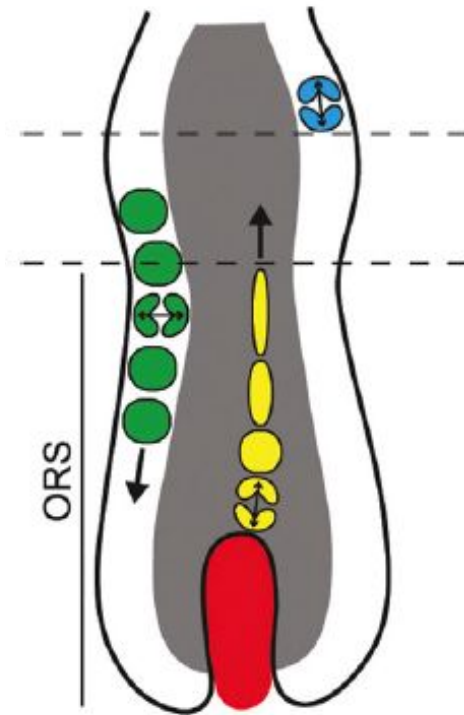


1. Bulge stem cells: quiescent and maintain long-term stem cell pool
2. Hair germ cells: activated during anaphase engaging in a new growth

Hair Follicle Regeneration

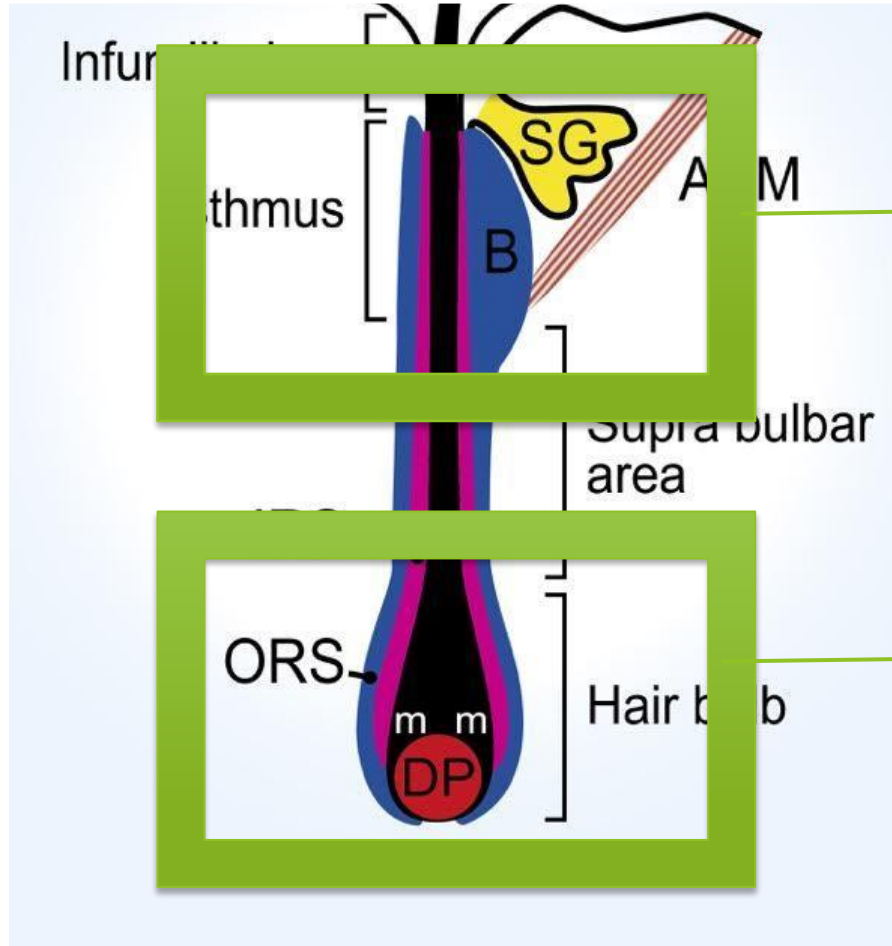


Immune Privilege



Special environment
permitting escape from
the host immune system
detection

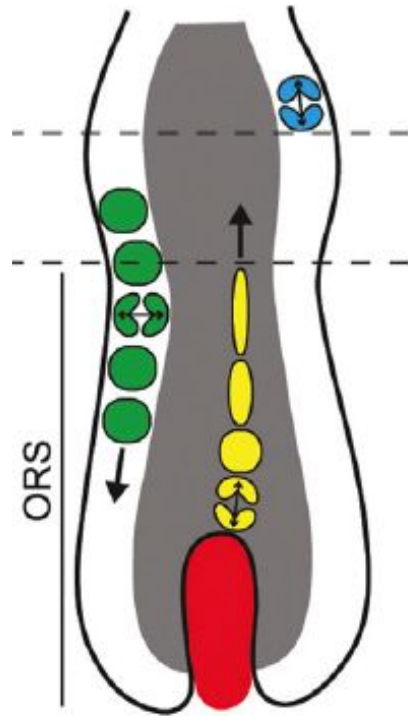
Immune Privilege



Permanent immune privilege

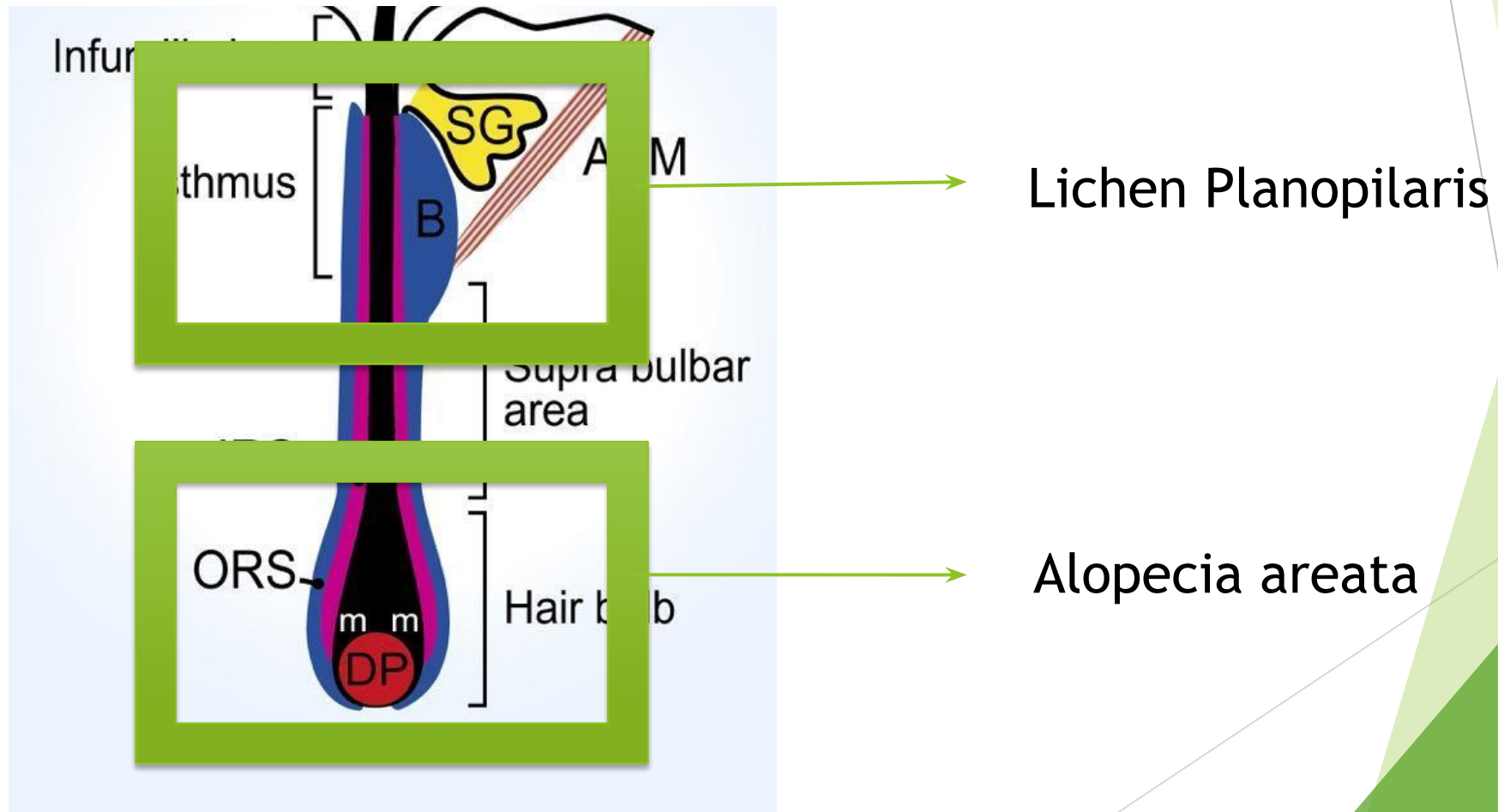
Temporary immune privilege during anagen phase

Anagen phase

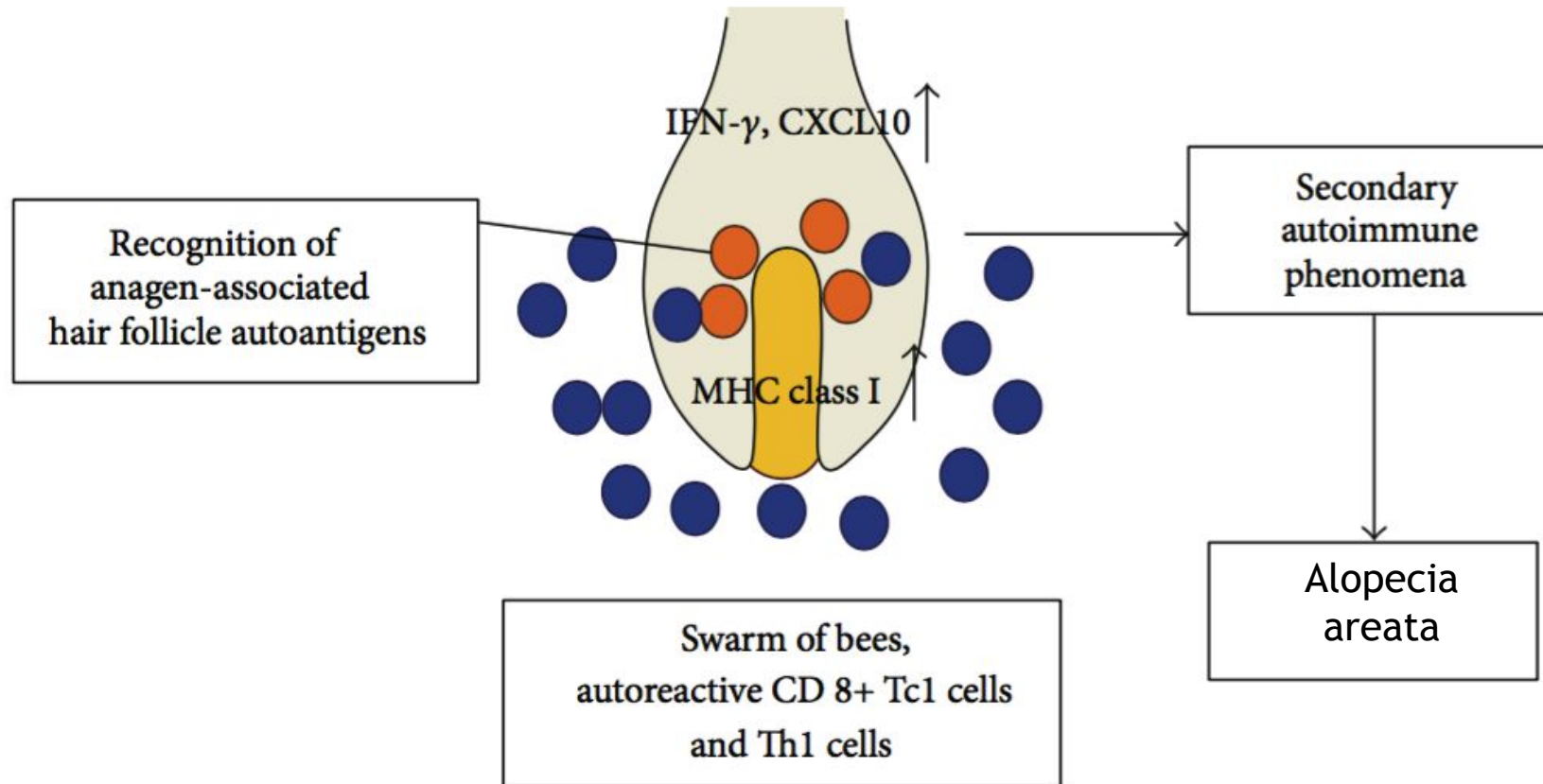


Immune injury

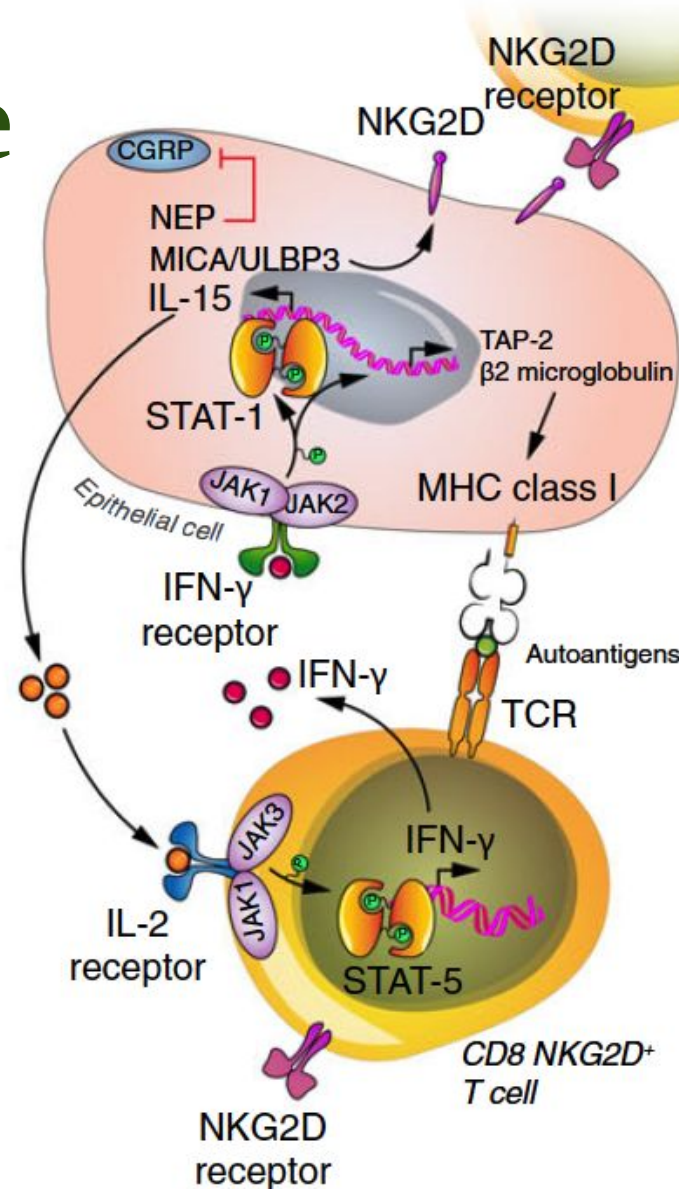
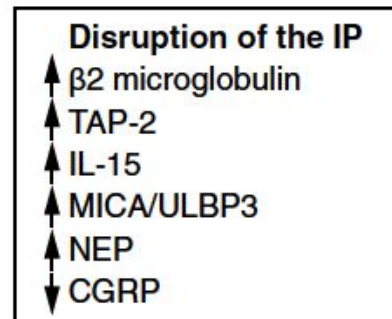
Immune Privilege Collapse



Immune privilege collapse in Alopecia areata



Immune privilege collapse in alopecia areata



Lichen planopilaris is characterized by immune privilege collapse of the hair follicle's epithelial stem cell niche

Matthew J Harries,¹ Katja Meyer,² Iskander Chaudhry,³ Jennifer E Kloepper,² Enrique Poblet,⁴ Christopher EM Griffiths¹ and Ralf Paus^{1,2*}

¹ Dermatology Centre, Salford Royal NHS Foundation Trust, University of Manchester, Manchester Academic Health Science Centre, UK

² Department of Dermatology, University of Lübeck, Germany

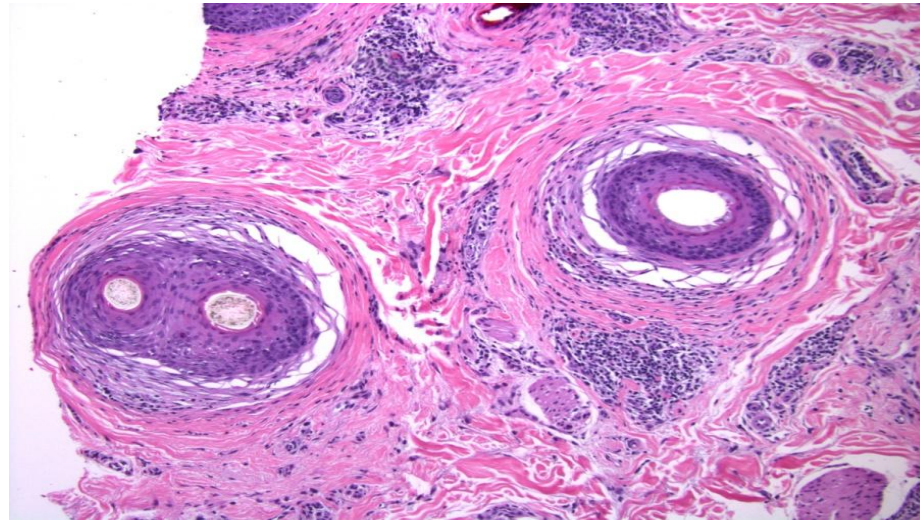
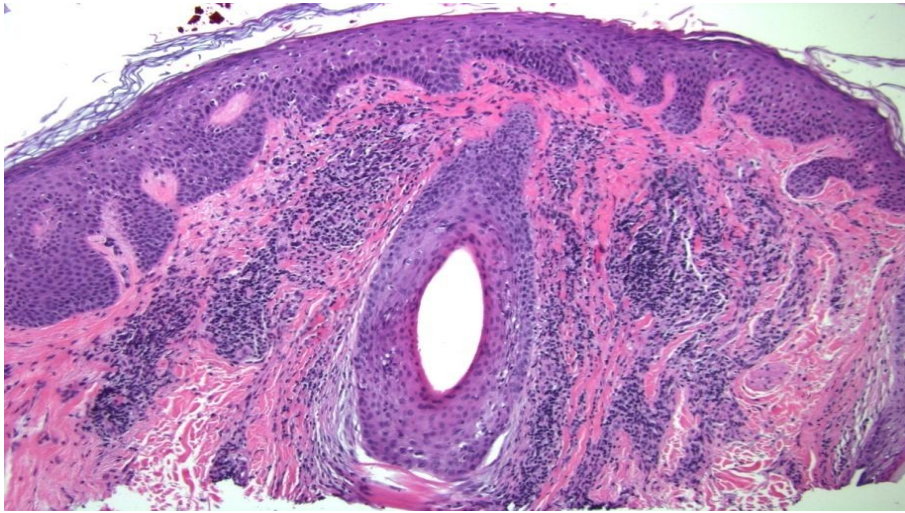
³ Department of Pathology, Central Manchester NHS Foundation Trust, UK

⁴ Department of Pathology, University General Hospital of Murcia, Spain

*Correspondence to: R Paus, Department of Dermatology, University of Lübeck, Lübeck, Germany. E-mail: ralf.paus@uksh.de or ralf.paus@manchester.ac.uk

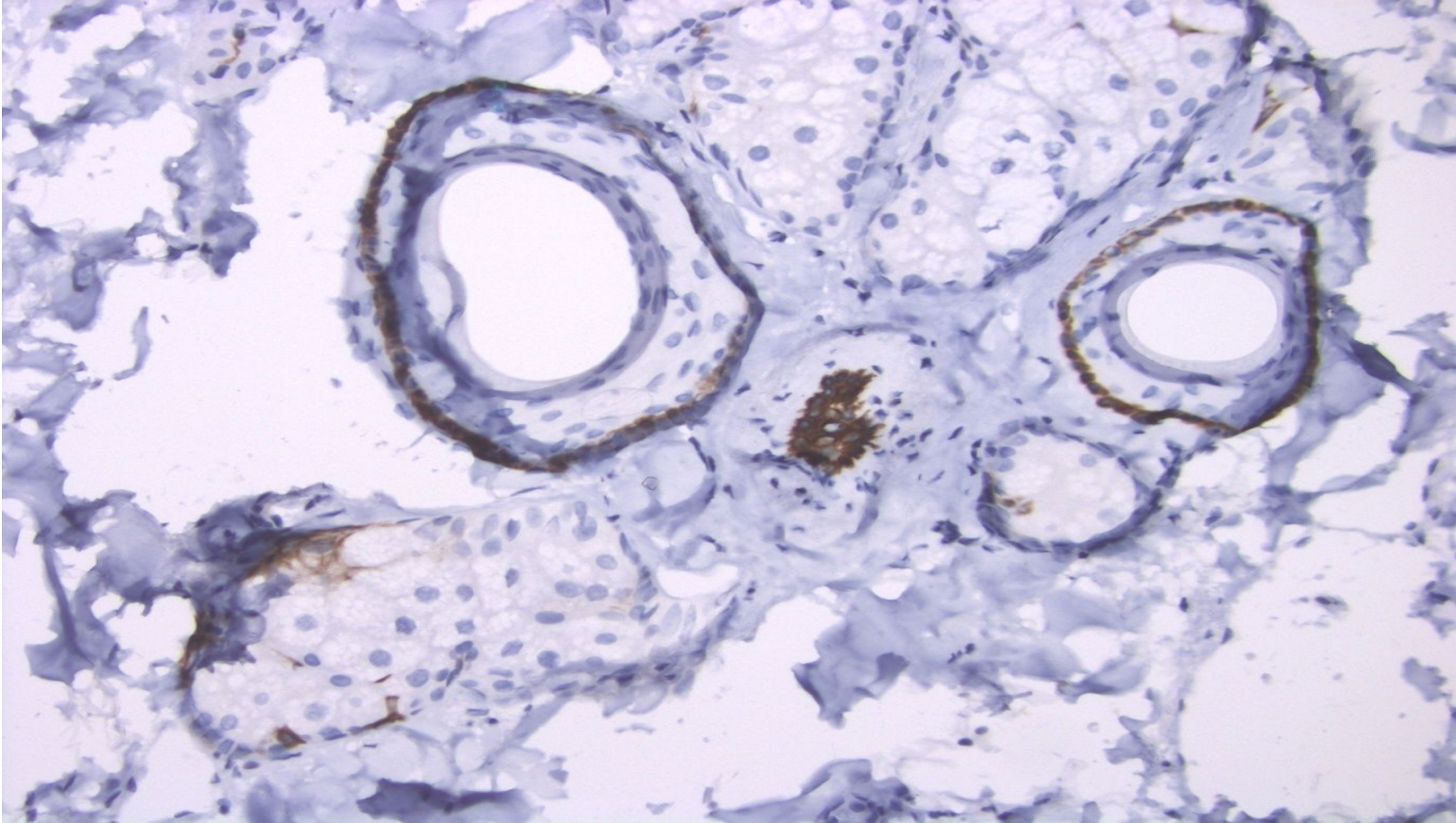
“These novel findings raise the possibility that LPP represents an autoimmune disease in whose pathogenesis IFN γ -induced bulge immune privilege collapse plays an important role.”

Lichen Planopilaris (LPP)

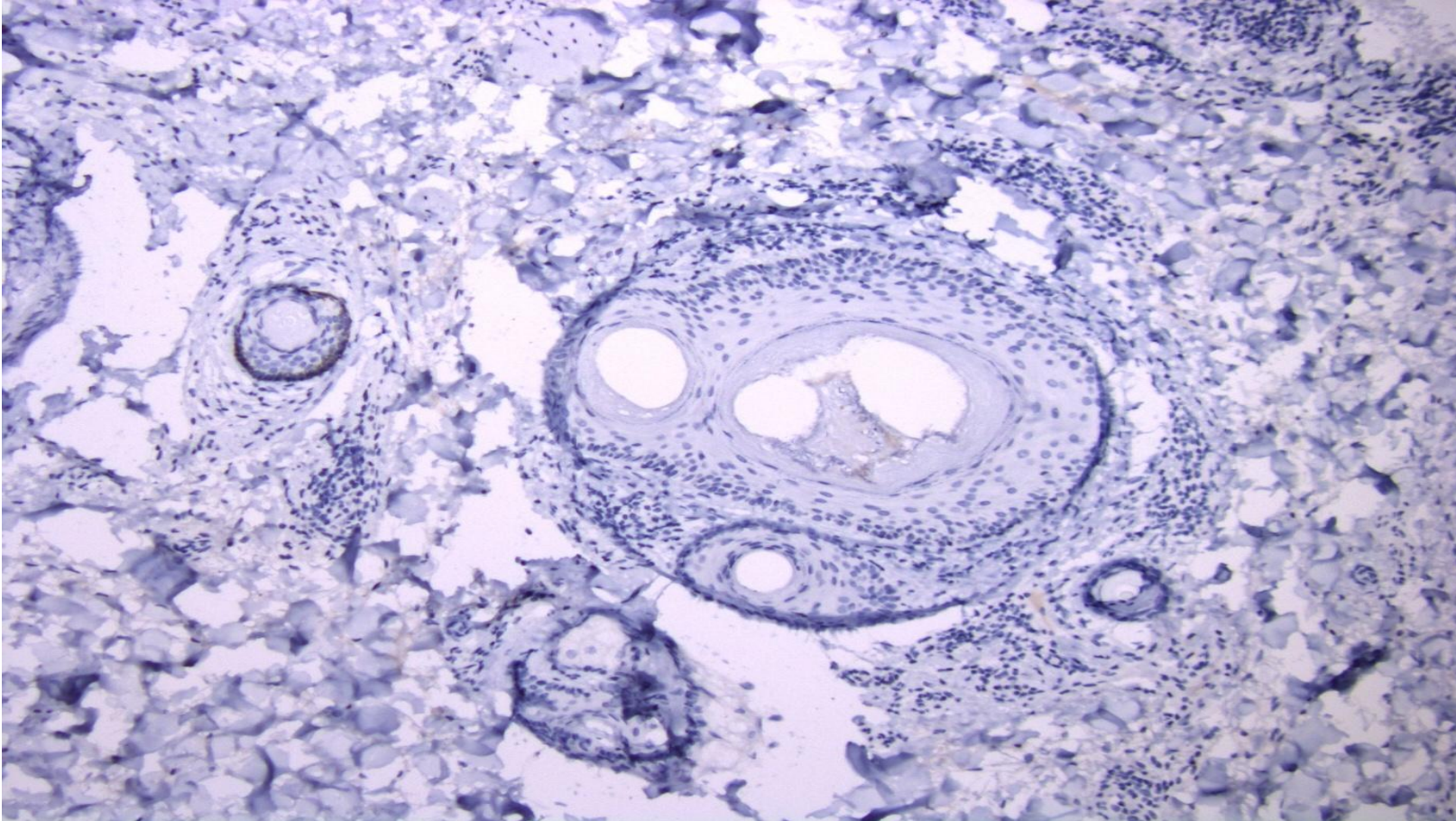


Loss of catagen/telogen phase follicles

Cytokeratin 15+ Stem Cells

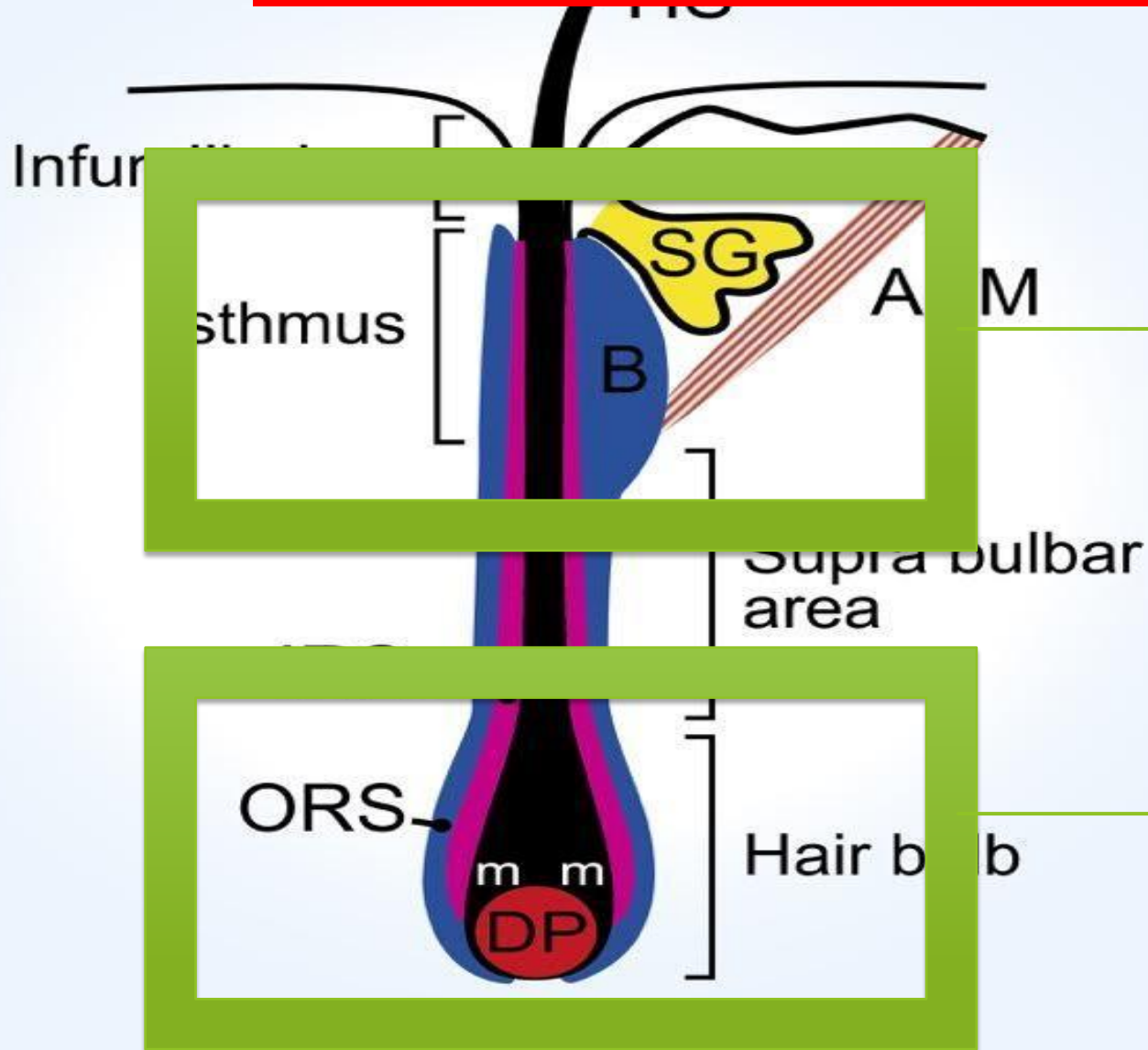


CK15 Loss in Lichen Planopilaris



Habashi-Daniel et al. Absence of catagen/telogen phase and loss of cytokeratin 15 expression in hair follicles in lichen planopilaris. *JAAD* 71:969-72, 2014.

AA and LPP-like pattern



LPP-like pattern

1. Absence of follicular miniaturization
2. No or few CT hair

AA-like pattern

1. Marked follicular miniaturization
2. Increase of CT hair



Key Points

I. Before signing out as AA:

1. Check the epidermis
2. Antinuclear antibodies and syphilis serology
3. Syphilis immunostain

II. New, unifying concept of alopecia based upon hair follicle immunology and follicular cell kinetics rather than the nature of the inflammatory cell infiltrate.



Portland, Oregon USA



Brussels, Belgium



Curtis Thompson, MD
curtisinportland@gmail.com
www.cta-lab.com



Athanassios Kolivras, MD, PhD
kolivras@gmail.com

Thank you!



Portland, Oregon USA



Brussels, Belgium



Janet Roberts, MD
janetrobertsmd@gmail.com



Curtis Thompson, MD
curtisinportland@gmail.com
www.cta-lab.com



Athanassios Kolivras, MD, PhD
kolivras@gmail.com

Thank you!
ありがとうございます