

Coronavirus (COVID-19) infection–induced chilblains: A case report with histopathologic findings



Athanassios Kolivras, MD, PhD,^a Florence Dehavay, MD,^a Daphné Delplace, MD,^b Francesco Feoli, MD,^a Isabelle Meiers, MD,^a Lorenzo Milone, BS,^c Catherine Olemans, MD,^a Ursula Sass, MD,^a Anne Theunis, MD,^a Curtis T. Thompson, MD,^{d,e} Laura Van De Borne, MD,^a and Bertrand Richert, MD, PhD^a
Brussels and Ath, Belgium; and Portland, Oregon

INTRODUCTION

Until now, the skin findings reported in association with coronavirus disease 2019 (COVID-19) infection remain sparse, nonspecific, and devoid of any prognostic significance.^{1,2} This case report emphasizes a novel cutaneous sign of utmost importance for dermatologists to recognize.

CASE REPORT

A 23-year-old man presented with a 3-day history of acute-onset, violaceous, infiltrated, and painful plaques on the toes and lateral aspect of the feet. The appearance of the plaques was preceded by 3 days of a low-grade fever (37.7°C) and a dry cough. His clinical history was notable for psoriasis, which had been treated with secukinumab for 30 months; however, the secukinumab had been stopped 1 month before to minimize immunosuppression during the COVID-19 pandemic. No additional treatment had been initiated.

The patient had many violaceous, infiltrated, and painful plaques on an erythematous background on the dorsal aspect of the toes and the lateral sides of the feet (Fig 1). The hands and fingers were unaffected. The patient did not have a history of Raynaud phenomenon, acrocyanosis, chilblains (perniosis), or photosensitivity. A complete skin examination result was otherwise unremarkable, and dermoscopy showed normal proximal nail folds. A

Abbreviations used:

COVID-19: coronavirus disease 2019
 IFN-I: type I interferon

complete blood cell count; erythrocyte sedimentation rate; coagulation study results (prothrombin time, activated partial thromboplastin time, and thrombin time); a D-dimer test result; renal, hepatic, and thyroid function test results; an antinuclear antibody test; and an Epstein-Barr serology result were either within normal limits or negative. Urine was devoid of protein or blood. Finally, a polymerase chain reaction (PCR) test result for Severe acute respiratory syndrome coronavirus 2 (COVID-19), performed on a nasopharyngeal swab, was positive.

A 4-mm punch biopsy was obtained from the edge of an ulcerated lesion on the dorsal third toe of the right foot. Histopathology showed a superficial and deep lichenoid, perivascular, and perieccrine infiltrate of lymphocytes, with occasional plasma cells. There was vacuolar alteration along the basal layer of the epidermis, with scattered singly necrotic (apoptotic) keratinocytes, which were occasionally present in the superficial layers of the epidermis (Fig 2). The basement membrane zone was smudged, and there was papillary dermal fibrin confined near the ulcer edge. There was no pallor (edema) of the

From the Department of Dermatology, Saint-Pierre–Brugmann and Children’s University Hospitals, Université Libre de Bruxelles, Brussels^a; private dermatology practice, Ath^b; Université Libre de Bruxelles, Brussels^c; CTA Lab, Portland^d; and Departments of Dermatology and Pathology, Oregon Health & Science University.^e

Funding sources: None.

Conflicts of interest: None disclosed.

Correspondence to: Athanassios Kolivras, MD, PhD, Department of Dermatology, Saint-Pierre Hospital, 129 boulevard de Waterloo, 1000 Brussels, Belgium. E-mail: kolivras@gmail.com.

JAAD Case Reports 2020;6:489-92.

2352-5126

© 2020 by the American Academy of Dermatology, Inc. Published by Elsevier, Inc. This is an open access article under the CC BY-NC-ND license (<http://creativecommons.org/licenses/by-nc-nd/4.0/>).

<https://doi.org/10.1016/j.jidcr.2020.04.011>

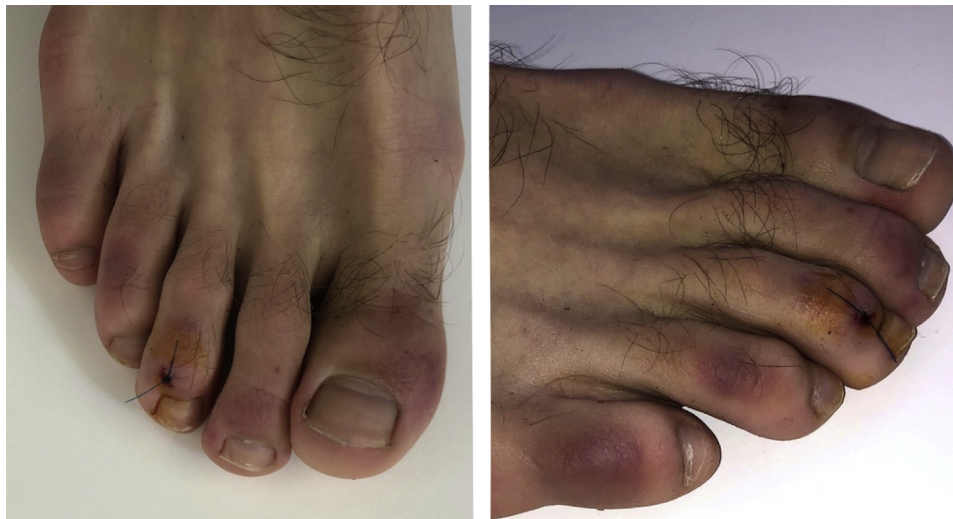

Fig 1. Coronavirus disease 2019–induced chilblains. Violaceous infiltrated plaques that appeared abruptly on an erythematous background, with features typical of chilblains.

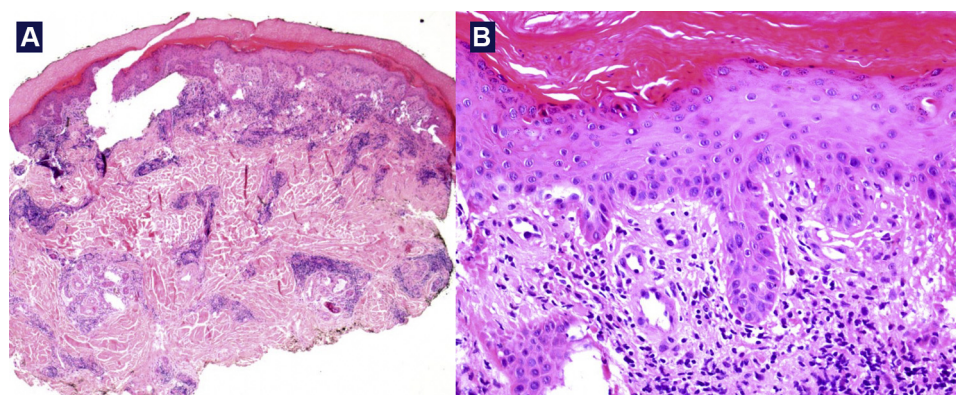


Fig 2. Coronavirus disease 2019–induced chilblains. **A**, Histopathologic findings simulating chilblain lupus with an absence of significant papillary dermal edema. There is a superficial and deep lymphoplasmacytic infiltrate. **B**, Vacuolar interface dermatitis with singly necrotic (apoptotic) keratinocytes and smudging of the basement membrane zone. Some of the necrotic keratinocytes are in the superficial layers of the epidermis. (Hematoxylin-eosin stain.)

papillary dermis. The infiltrate was dense and lichenoid in the papillary and superficial reticular dermis, and the deeper dermis had a tightly cuffed perivascular and periecrine distribution (Fig 3). Some nuclear debris was present, but no neutrophils were identified. The venules surrounded by the lymphoplasmacytic infiltrate had plump endothelial cells. No intraluminal fibrin thrombi were identified, and no fibrin was identified within venule walls. Direct immunofluorescence result was negative. In accordance with these features, a diagnosis of COVID-19 infection–induced chilblains was made.

DISCUSSION

COVID-19 infection–induced chilblains have been observed during the pandemic and

communicated among the French and Belgian dermatologic networks. To our knowledge, it had not been previously reported because of the limited availability of PCR testing for COVID-19. Young patients presenting with chilblains have lacked criteria sufficient to allow for a COVID-19 PCR test. Because of the recent outbreak of chilblains, concurrent with the increase of COVID-19 cases, COVID-19 has been widely suspected as the etiology. We have further suspected an association because chilblains have been appearing during the warmer springtime rather than the usual cold winter period. Similar to this case, other young patients presenting with chilblains have also lacked a history of chilblains, Raynaud phenomenon, or collagen vascular diseases such as lupus erythematosus.

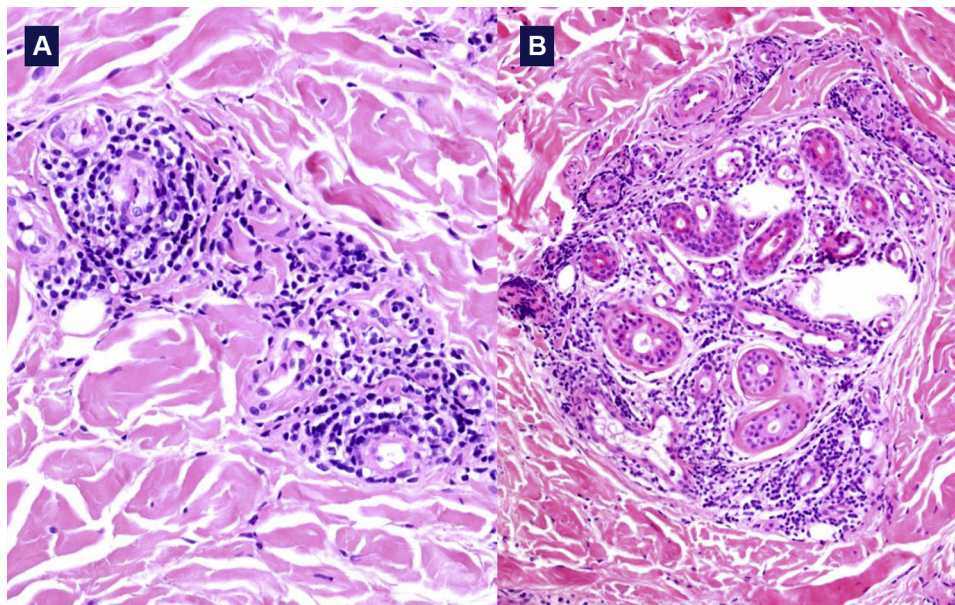


Fig 3. Coronavirus disease 2019–induced chilblains. **A**, A predominantly lymphocytic infiltrate with occasional plasma cells, which is tightly cuffing vessels whose walls and lumina are devoid of fibrin deposition and thrombi. **B**, A perieccrine accentuation to the infiltrate. (Hematoxylin-eosin stain.)

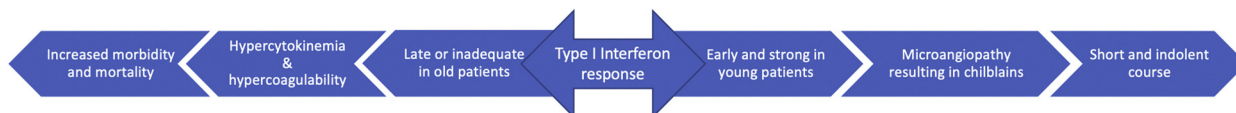

Fig 4. Coronavirus disease 2019–induced chilblains. Coronavirus primo infection–induced chilblains (perniosis) may represent microangiopathic changes induced by an increased type I interferon reaction. The reaction may protect the host from viral replication, thereby explaining why young patients run a short and indolent course of the disease in contrast to older patients with a delayed or insufficient type I interferon reaction, resulting in increased morbidity and mortality.

These cases have all been in children and young adults whose feet have been more affected than their hands. Chilblains may be the only symptom of COVID-19, and a fever and dry cough may be minimal or even absent. These patients appear to have an indolent course, often not knowing that they have a COVID-19 infection and that they are likely contagious. Acute acral cyanosis in the absence of chilblains has also been observed (unpublished data).

The clinical and histopathologic similarities to chilblain lupus erythematosus are striking but not surprising, given our knowledge of type I interferons (IFN-I). The antiviral and immunostimulatory properties of IFN-I during acute viral infections, like Epstein-Barr infection, are well established, as well as the IFN-I signature in lupus erythematosus, whose pathogenesis simulates a viral-induced immunoresponse.^{3,4} The clinical presentation of IFN-I signature

is observed within the monogenic autoinflammatory interferonopathies, which, like chilblain lupus erythematosus, are characterized by a microangiopathy that produces clinical chilblains. Among these syndromes, the most representative are the overlap between Aicardi-Goutières syndrome and familial chilblain lupus and the stimulator of IFN genes-associated vasculopathy with onset in infancy.^{5,6} The aforementioned interferonopathies share both a clinical and biological overlap with lupus erythematosus.

COVID-19 robustly triggers the expression of IFN-inducible genes that assist in the host’s antiviral protection. This IFN-I activation of these genes, however, can be deleterious, especially when their expression is delayed. This may exacerbate concurrent hypercytokinemia (the so-called cytokine storm).⁷ Some authors have also reported that COVID-19 elicits a muted cytokine response, lacking

a robust induction of IFN-I.⁸ We suspect, however, that this muted response is observed in an older patient population.

We therefore hypothesize that young patients exhibit an early IFN-I response, thereby muting early viral replication. The IFN-I response, however, induces microangiopathic changes, producing a chilblain lupus erythematosus–like eruption. Older patients, unfortunately, may have an inadequate or delayed IFN-I response, exacerbating preexisting hypercytokinemia, with subsequent increased morbidity and mortality. Chilblain lupus erythematosus–like lesions in young people should not be confused with the acral ischemia caused by thrombosis that is being observed in severely ill COVID-19 patients. These patients, usually in the intensive care unit, have hypercoagulopathy and elevated D-dimer levels.⁹ Thus, the IFN-I response in young patients may be advantageous, whereas the delayed or insufficient IFN-I response in older patients may be disadvantageous. In short, COVID-19 infection–induced chilblains may portend an indolent course and a good prognosis (Fig 4).

To our knowledge, this is the first clinical and histopathologic report of COVID-19 infection–induced chilblains. Until our observation can be further validated by larger studies, we urgently aim

to alert clinicians to this presentation of chilblains in paucisymptomatic young patients who need to be immediately tested and isolated.

REFERENCES

1. Recalcati S. Cutaneous manifestations in COVID-19: a first perspective [epub ahead of print]. *J Eur Acad Dermatol Venereol*. 2020. <https://doi.org/10.1111/jdv.16387>.
2. Zheng Y, Lai W. Dermatology staff participate in fight against Covid-19 in China [epub ahead of print]. *J Eur Acad Dermatol Venereol*. 2020. <https://doi.org/10.1111/jdv.16390>.
3. Saeed M. Lupus pathobiology based on genomics. *Immunogenetics*. 2017;69:1-12.
4. Ivashkiv L, Donlin L. Regulation of type I interferon responses. *Nat Rev Immunol*. 2014;14:36-49.
5. Kolivras A, Aeby A, Crow Y, et al. Cutaneous histopathological findings of Aicardi-Goutières syndrome, overlap with chilblain lupus. *J Cutan Pathol*. 2008;35:774-778.
6. Munoz J, Marque M, Dandurand M, Meunier L, Crow Y, Bessis D. Interféronopathies de type I. *Ann Dermatol Venereol*. 2015;142:653-663.
7. Zhou Z, Ren L, Zhang L, et al. Overly exuberant innate immune response to SARS-CoV-2 infection [epub ahead of print]. *Cell Host Microbe*. 2020. <https://doi.org/10.2139/ssrn.3551623>.
8. Blanco-Melo D, Nilsson-Payant B, Liu W, et al. SARS-CoV-2 launches a unique transcriptional signature from in vitro, ex vivo, and in vivo systems [epub ahead of print]. *BioRxiv*. 2020. <https://doi.org/10.1101/2020.03.24.004655>.
9. Zhang Y, Cao W, Xiao M, et al. Clinical and coagulation characteristics of 7 patients with critical COVID-2019 pneumonia and acro-ischemia. *Zhonghua Xue Ye Xue Za Zhi*. 2020;41:E006.