
A method for more precise sampling of the scalp and eyebrows in frontal fibrosing alopecia



Curtis T. Thompson, MD,^{a,b,c} and Antonella Tosti, MD^d
Portland, Oregon, and Miami, Florida

Key words: alopecia; biopsy; cicatricial; FFA; frontal fibrosing alopecia; lichen planopilaris; LPP; scarring.

TECHNICAL CHALLENGE

Early diagnosis of frontal fibrosing alopecia (FFA) often requires performing a biopsy on a cosmetically sensitive area, such as the widow's peak or eyebrows.¹

SOLUTION

We present a modified, horizontal sectioning technique² that allows identification of diagnostic features from a 2-mm dermoscopy-guided punch biopsy specimen (Fig 1).³ The biopsy specimen is first sent through histologic processing without sectioning or inking. After processing, the specimen is embedded epidermis down. The initial sections contain the epidermis, and the subsequent horizontal step-level sections are taken through the entire tissue segment for a total of 3 slides (3 sections per slide). A few unstained slides are obtained between each of the 3 slides) for possible special stains or research because no tissue remains in the paraffin block (Fig 2).

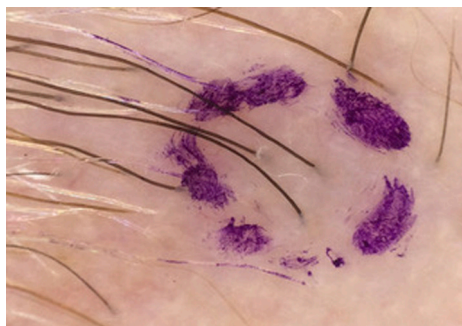


Fig 1. Dermoscopic image of a terminal hair with a peripilar cast, outlined before the 2-mm biopsy specimen is obtained.

From the CTA Lab, Portland^a; Department of Dermatology^b and Department of Pathology, Oregon Health and Sciences University, Portland^c; and Department of Dermatology, University of Miami Miller School of Medicine.^d

Funding sources: None.

Conflicts of interest: None disclosed.

Reprints not available from the authors.

Correspondence to: Curtis T. Thompson, MD, Oregon Health and Sciences University, Departments of Dermatology and

Pathology, PO Box 230577, Portland, OR 97281. E-mail: curtisinportland@gmail.com.

J Am Acad Dermatol 2019;80:e155-6.

0190-9622/\$36.00

© 2018 by the American Academy of Dermatology, Inc.

<https://doi.org/10.1016/j.jaad.2018.12.033>

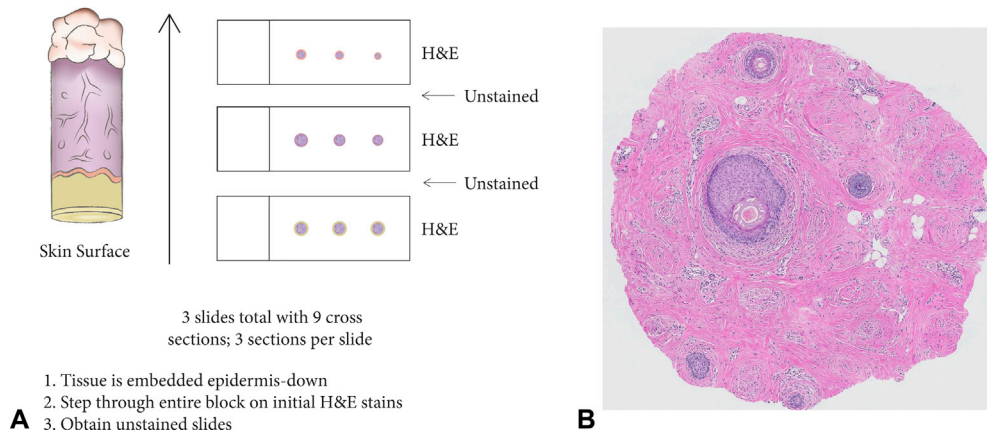


Fig 2. A, Transverse sectioning of an unsectioned, 2-mm punch biopsy specimen with hematoxylin and eosin (H&E)-stained and unstained slides being obtained through the entirety of the tissue segment. **B**, A 2-mm transverse section from an eyebrow biopsy showing marked follicular loss and slight fibrosis, with a few lymphocytes around 1 altered follicle.

The diagnostic histologic features of FFA are often quite subtle, involving a single vellus follicle. The inflammatory focus is usually superficial, being seen only in early sections; however, 1 case showed a single inflammatory focus on the last of the 9 sections. There is usually a low follicular density from follicular dropout. There is often little to no perifollicular fibrosis because FFA involves small follicles that have a short follicular cycle and drop out easily. Eyebrow biopsy specimens sometimes show no remaining follicular epithelium and only interstitial lymphocytes.

REFERENCES

1. Anzai A, Donati A, Valente NY, et al. Isolated eyebrow loss in frontal fibrosing alopecia: relevance of early diagnosis and treatment. *Br J Dermatol*. 2016;175(5):1099-1101.
2. Headington J. Transverse microscopic anatomy of the human scalp: a basis for a morphometric approach to disorders of the hair follicle. *Arch Dermatol*. 1984;120:449-456.
3. Miteva M, Tosti A. Dermoscopy guided scalp biopsy in cicatricial alopecia. *J Eur Acad Dermatol Venereol*. 2013;27(10):1299-1303.