

# Macular arteritis associated with concurrent HIV and hepatitis B infections: a case report and evidence for a disease spectrum association with cutaneous polyarteritis nodosa

We report the first case of macular arteritis in a 33-year-old Black, African female with concurrent human immunodeficiency virus (HIV) and hepatitis B virus (HBV) infections. Of particular interest in macular arteritis is the striking discordance between the clinical presentation and the histopathological findings, a fact that both dermatologists and dermatopathologists should be aware. Histopathologically, the case showed typical findings of macular arteritis with a perivascular, predominantly lymphocytic, infiltrate and intraluminal thrombosis. Both HIV and HBV have been reported as viral inducers of cutaneous polyarteritis nodosa (PAN). Their association with macular arteritis in this case supports existing evidence that macular arteritis and cutaneous PAN represent a single-disease spectrum of vasculitides, with macular arteritis representing the chronic, lymphocytic and indolent stage, and cutaneous PAN the neutrophilic, acute stage with a risk for systemic progression. Lymphocytic thrombophilic arteritis (LTA), a third, uncommon disease would be in between macular arteritis and cutaneous PAN on a spectrum. Features of this case and other published cases provide strong evidence that there is a single, mild-to-severe disease spectrum of macular arteritis-LTA-cutaneous PAN.

**Keywords:** dermatology, dermatopathology, human immunodeficiency virus (HIV), vasculitis

Kolivras A, Thompson C, Metz T, André J. Macular arteritis associated with concurrent HIV and hepatitis B infections: a case report and evidence for a disease spectrum association with cutaneous polyarteritis nodosa.

J Cutan Pathol 2015. © 2015 John Wiley & Sons A/S. Published by John Wiley & Sons Ltd

**Athanasios Kolivras<sup>1</sup>, Curtis Thompson<sup>2</sup>, Tanguy Metz<sup>3</sup> and Josette André<sup>1</sup>**

<sup>1</sup>Departments of Dermatology and Dermatopathology, Saint-Pierre, Brugmann and HUDERF Hospitals, Université Libre de Bruxelles, Brussels, Belgium,

<sup>2</sup>Departments of Biomedical Engineering, Pathology and Dermatology, Oregon Health Sciences University, Portland, OR, USA, and

<sup>3</sup>Department of Dermatology, Saint-Pierre, Brugmann and HUDERF Hospitals, Université Libre de Bruxelles, Brussels, Belgium

Athanasios Kolivras  
Departments of Dermatology and Dermatopathology, Saint-Pierre, Brugmann and HUDERF hospitals, Université Libre de Bruxelles, Brussels, Belgium  
e-mail: kolivras@gmail.com

Accepted for publication February 1, 2015

Macular arteritis, also called macular lymphocytic arteritis, is a medium-sized vessel lymphocytic arteritis. It is characterized by a striking

discordance between the clinical presentation and the histopathologic findings. Clinically, macular arteritis presents with hyperpigmented

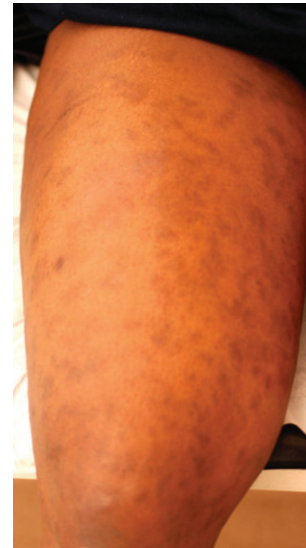macules, and, histopathologically, there is a lymphocytic vasculitis associated with endarteritis obliterans and intraluminal thrombi.<sup>1-4</sup>

We report the first case of macular arteritis associated with concurrent human immunodeficiency virus (HIV) and hepatitis B virus (HBV) infections. These viruses have been previously reported as viral inducers of cutaneous polyarteritis nodosa (PAN). Their association with macular arteritis supports the hypothesis that macular arteritis and cutaneous PAN represent a single-disease spectrum of vasculitides; macular arteritis, representing the chronic, lymphocytic and indolent stage, and cutaneous PAN the neutrophilic, acute stage, with a risk for systemic progression.<sup>5-8</sup> A third uncommon entity, lymphocytic thrombophilic arteritis (LTA), would probably be in between macular arteritis and cutaneous PAN on a disease spectrum (macular arteritis-LTA-cutaneous PAN).

### **Case report**

A 33-year-old Black, African female presented with a 10-year history of hyperpigmented, asymptomatic macules. The lesions initially appeared on the distal limbs and progressively extended proximally and onto the trunk. The patient was HIV-antibody positive, but she was not receiving any medication because she reportedly had no immune suppression. HIV-viral particles remained undetectable. She was hepatitis B S-antigen and S-antibody positive with normal liver function. The rest of the clinical history was unremarkable.

On clinical examination, there were numerous hyperpigmented macules on the lower limbs, and, to a lesser extent, on the upper extremities and the trunk (Fig. 1). The macules were rounded and ill-defined, with some lesions being slightly infiltrated on palpation. The macules were also distributed in a racemosa (grape-like) pattern (Fig. 2). The patient carried a diagnosis of post-inflammatory pigmentary alteration (PIPA); however, PIPA was not probably because of the absence of any prior inflammatory lesions or a history of topical medication use. Laboratory studies showed an increased erythrocyte sedimentation rate (ESR) and positive anticardiolipin and anti- $\beta_2$  glycoprotein-1 antibodies. A complete blood count, hepatic, renal and thyroid function, antinuclear antibodies, anti-neutrophilic cytoplasmic antibodies (ANCA), complement levels, and urine analysis were all normal or negative.



*Fig. 1.* Numerous hyperpigmented macules involved the lower limbs.



*Fig. 2.* The macules were rounded and ill-defined, with some lesions being slightly infiltrated on palpation.

A skin biopsy from the right thigh showed an unremarkable epidermis, and papillary and superficial reticular dermis. Medium-sized muscular vessels within the deep reticular dermis near the dermal-subcutaneous junction were altered. There were perivascular and intramural lymphocytes (Fig. 3). Scattered plasma cells were present. Leukocytoclasia was present, and there were intraluminal thrombi with hyalinized fibrin rings (lines of Zahn) (Fig. 4). The muscular composition of the medium-sized vessel was seen best with an orcein stain, which revealed an internal elastic lamina.

The clinical presentation of hyperpigmented macules associated with the histopathologic findings of a medium-sized vessel lymphocytic arteritis led to a diagnosis of macular arteritis.

## Macular arteritis associated with concurrent HIV and hepatitis B infections

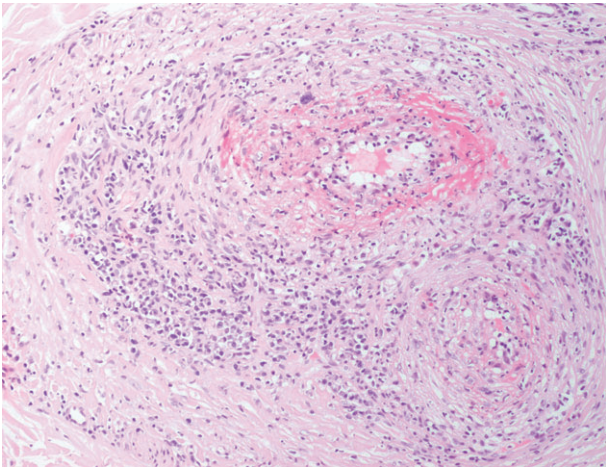


Fig. 3. Altered medium-sized vessels were within the deep reticular dermis with perivascular and intramural lymphocytes.

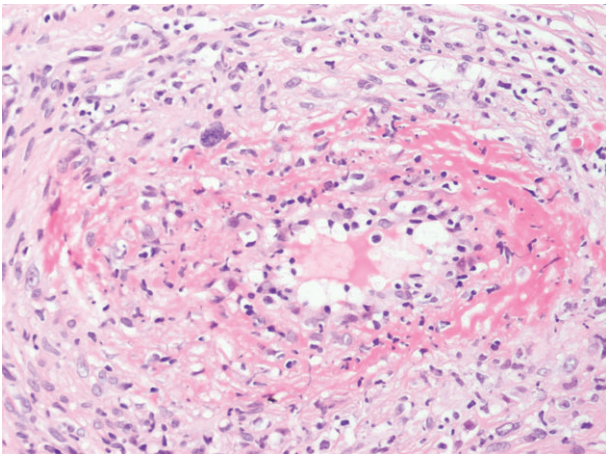


Fig. 4. Leukocytoclasia was present, and there were intraluminal thrombi with hyalinized fibrin rings.

### Discussion

We report the first case of macular arteritis in a patient with concurrent HIV and HBV infection. Since macular arteritis was first described by Fein et al.<sup>4</sup>, it has mostly been reported in African-American and Asian females, usually presenting with ill-defined hyperpigmented macules with a round-linear and, rarely, a reticulated morphology.<sup>1,4,9</sup>

Of note in macular arteritis, the process of concentric, luminal fibrin deposition, fibro-intimal scarring, luminal narrowing, thrombus formation and endarteritis obliterans does not lead to either melanin or hemosiderin deposition. The reason for the clinical hyperpigmentation is, thus, not explained by the histopathologic findings. The hyperpigmentation is, therefore, probably the result of reduced flow because of the destructive vascular process.

The striking discordance between the clinical appearance and the histopathophysiologic findings remains the hallmark of macular arteritis.<sup>2,5,8</sup> The term 'macular' is not an accurate clinical description when one considers the presence of palpable, inflamed arteries. Indeed in our case, the lesions were slightly infiltrated upon palpation. There are also reports of macular arteritis mimicking persistent pigmented-purpuric dermatosis (PPPD),<sup>10</sup> including one in a 6-year-old Caucasian girl.<sup>11</sup> Thus, it is important for clinicians to have knowledge of macular arteritis and the clinical-histopathologic discordance in order to be able to make a definitive diagnosis.

There is clinical support for a macular arteritis-LTA-cutaneous PAN spectrum, an idea proposed by some authors, with macular arteritis representing a subtle, indolent and reparative form of cutaneous PAN.<sup>5-8</sup> In macular arteritis, clinical findings are limited to hyperpigmented macules with no systemic involvement. LTA patients typically develop livedo racemosa with the cutaneous lesions being more infiltrated and plaque-like than in macular arteritis. Systemic symptoms such as arthralgia and myalgia may also be present in LTA. Cutaneous findings in macular arteritis and LTA are limited to manifestations linked to the reduced blood flow (hyperpigmentation and livedo racemosa), and the patients lack findings of cutaneous PAN resulting from the acute vasculitis with acute vascular destruction, with painful nodules, palpable purpura and ulceration. In cutaneous PAN, there is also a risk for developing neuropathy and progression to systemic disease (<1% of patients).

Cutaneous PAN is associated with immune complex deposition and an acute, destructive neutrophilic vasculitis with recurrent flares, whereas macular arteritis and LTA are chronic and slowly progressive with a predominantly lymphocytic infiltrate. We do not know if there is immune complex deposition at the onset of LTA and macular arteritis or if an acute form of cutaneous PAN is sometimes a precursor to the chronic LTA or macular arteritis phase. Our patient did not present any flares, and clinical manifestations were limited to macular arteritis. Mixed clinical presentations with features of macular arteritis, LTA and cutaneous PAN have also been described.<sup>5</sup>

Laboratory studies provide some support for a macular arteritis-LTA-cutaneous PAN spectrum, but they also show differences among the disease entities. Serologic markers for inflammation (ESR) are also more prevalent along a

macular arteritis-LTA-cutaneous PAN spectrum, but antinuclear antibodies and antiphospholipid antibodies are more frequently detected in LTA than in macular arteritis and cutaneous PAN.<sup>3,5</sup> P-ANCA may be present in 10–20% patients with cutaneous PAN, but it is not known whether P-ANCA is significantly present in macular arteritis and LTA. Ultimately, understanding of a macular arteritis, LTA and cutaneous PAN relationship will depend on a better understanding of vascular damage from both immune complex deposition and a lymphocyte-mediated mechanism.

Our case shows interesting mixed features, both clinically and serologically. Whereas our patient showed the usual positivity of antiphospholipid antibodies seen in macular arteritis, the positivity for HIV and HBV have never been associated with macular arteritis.

Both HIV and HBV, however, have been identified as probable viral inductors of cutaneous PAN.<sup>12–17</sup> HBV has been reported in association with systemic PAN and even linked with a more aggressive course.<sup>18</sup> Perhaps our patient's immunocompetence, even with HIV and HBV infections, caused her to present as macular arteritis rather than cutaneous or systemic PAN, thereby producing a chronic, lymphocytic rather than an acute, neutrophilic arteritis.

## Conclusion

We present the first case of macular arteritis associated with concurrent HIV and HBV infections. This case and published experience both support the presence of a macular arteritis-LTA-cutaneous PAN disease spectrum.

## References

1. Morruzzi C, Cribier B, Lipsker D. Macular arteritis. *Ann Dermatol Venereol* 2010; 137: 460.
2. Saleh Z, Mutasim DF. Macular lymphocytic arteritis: a unique benign cutaneous arteritis, mediated by lymphocytes and appearing as macules. *J Cutan Pathol* 2009; 36: 1269.
3. Lee JS, Kossard S, McGrath MA. Lymphocytic thrombophilic arteritis: a newly described medium-sized vessel arteritis of the skin. *Arch Dermatol* 2008; 144: 1175.
4. Fein H, Sheth AP, Mutasim DF. Cutaneous arteritis presenting with hyperpigmented macules: macular arteritis. *J Am Acad Dermatol* 2003; 49: 519.
5. Macareno RS, Galan A, Simoni PM, et al. Cutaneous lymphocytic thrombophilic (macular) arteritis: a distinct entity or an indolent (reparative) stage of cutaneous polyarteritis nodosa? Report of 2 cases of cutaneous arteritis and review of the literature. *Am J Dermatopathol* 2013; 35: 213.
6. Garcia C, Dandurand M, Roger P, Joujoux JM, Meunier L, Stoebner PE. Macular lymphocytic arteritis: three cases questioning its classification as primary lymphocytic vasculitis. *Dermatology* 2014; 228: 103.
7. Valverde R, Garrido C, Leis V, Ruiz-Bravo E. Macular arteritis: a pole of the spectrum of cutaneous polyarteritis nodosa? *Actas Dermosifiliogr* 2013; 104: 263.
8. Al-Daraji W, Gregory AN, Carlson JA. "Macular arteritis": a latent form of cutaneous polyarteritis nodosa? *Am J Dermatopathol* 2008; 30: 145.
9. Sadahira C, Yoshida T, Matsuoka Y, Takai I, Noda M, Kubota Y. Macular arteritis in Japanese patients. *J Am Acad Dermatol* 2005; 52: 364.
10. Llamas-Velasco M, García-Martín P, Sánchez-Pérez J, Sotomayor E, Fraga J, García-Diez A. Macular lymphocytic arteritis: first clinical presentation with ulcers. *J Cutan Pathol* 2013; 40: 424.
11. Buckthal-McCuin J, Mutasim DF. Macular arteritis mimicking pigmented purpuric dermatosis in a 6-year-old caucasian girl. *Pediatr Dermatol* 2009; 26: 93.
12. Peraire J, Vidal F, Mayayo E, Torre L, Richart C. Cutaneous polyarteritis nodosa in human immunodeficiency virus infection. *Br J Rheumatol* 1993; 32: 937.
13. Zoshima T, Matsumura M, Suzuki Y, et al. A case of refractory cutaneous polyarteritis nodosa in a patient with hepatitis B carrier status successfully treated with tumor necrosis factor alpha blockade. *Mod Rheumatol* 2013; 23: 1029.
14. Ventura F, Antunes H, Brito C, Pardal F, Pereira T, Vieira AP. Cutaneous polyarteritis nodosa in a child following hepatitis B vaccination. *Eur J Dermatol* 2009; 19: 400.
15. Tang MBY, Liew KVS, Ng PPL, Tan SH, Ng SK. Cutaneous polyarteritis nodosa associated with precore mutant hepatitis B infection. *Br J Dermatol* 2003; 149: 914.
16. Bourgeais AM, Dore MX, Croue A, Leclech C, Verret JL. Cutaneous polyarteritis nodosa following hepatitis B vaccination. *Ann Dermatol Venereol* 2003; 130: 205.
17. Bedani PL, Bergami M, Cavazzini PL, et al. HBV-related cutaneous periarthritis nodosa in a patient 16 years after renal transplantation: efficacy of lamivudine. *J Nephrol* 2001; 14: 428.
18. Pagnoux C, Seror R, Henegar C, et al. Clinical features and outcomes in 348 patients with polyarteritis nodosa: a systematic retrospective study of patients diagnosed between 1963 and 2005 and entered into the French Vasculitis Study Group Database. *Arthritis Rheum* 2010; 62: 616.