

# UC Davis

## Dermatology Online Journal

### Title

A slowly enlarging mass on the finger

### Permalink

<https://escholarship.org/uc/item/212957kk>

### Journal

Dermatology Online Journal, 20(2)

### Authors

Jefferson, Julie  
Thompson, Curtis  
Rich, Phoebe

### Publication Date

2014

### License

<https://creativecommons.org/licenses/by-nc-nd/4.0/> 4.0

Peer reviewed

## Case Presentation

### A slowly enlarging mass on the finger

Julie Jefferson MD<sup>1</sup>, Curtis Thompson MD<sup>2</sup>, and Phoebe Rich MD<sup>2</sup>

Dermatology Online Journal 20 (2): 5

<sup>1</sup>Department of Dermatology, Johns Hopkins Medicine, Baltimore, MD

<sup>2</sup>Department of Dermatology, Oregon Health and Science University, Portland, OR

### Correspondence:

Julie Jefferson, MD  
Department of Dermatology, Johns Hopkins Medicine  
1550 Orleans Street  
Baltimore, Maryland 21231 USA  
Phone: 803-603-5923  
E-mail: julieajeffersonmd@gmail.com

## Abstract

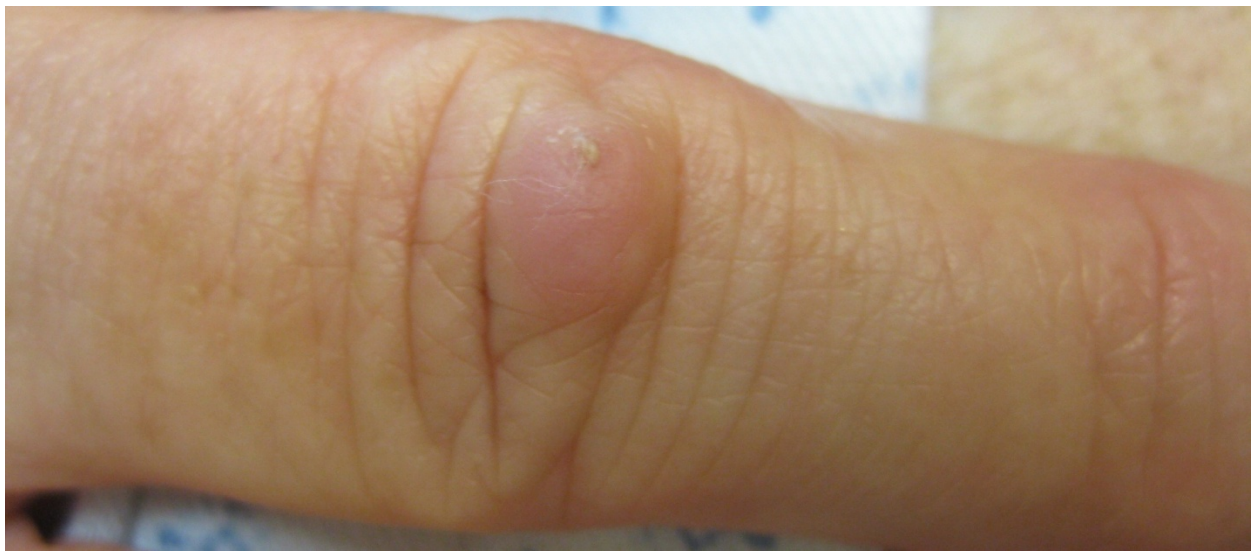An otherwise healthy 71-year-old woman presented with an asymptomatic mass on her right 4<sup>th</sup> finger that had been slowly enlarging over the past 2 years. On physical examination, there was a tan-pink, freely mobile, rubbery 9-mm papule with a central keratotic plug located over the extensor aspect of the proximal interphalangeal joint of the right 4<sup>th</sup> finger. A 3-mm punch biopsy of the lesion was performed. Histopathologic findings were consistent with a diagnosis of aggressive digital papillary adenocarcinoma (ADPAca), an adnexal tumor with high metastatic potential that is unfortunately commonly misdiagnosed owing to its rarity and nondescript appearance. Aggressive surgical treatment including radical excision or digital amputation with or without sentinel lymph node biopsy is advocated in the treatment of ADPAca.

**Keywords:** Aggressive digital papillary adenocarcinoma

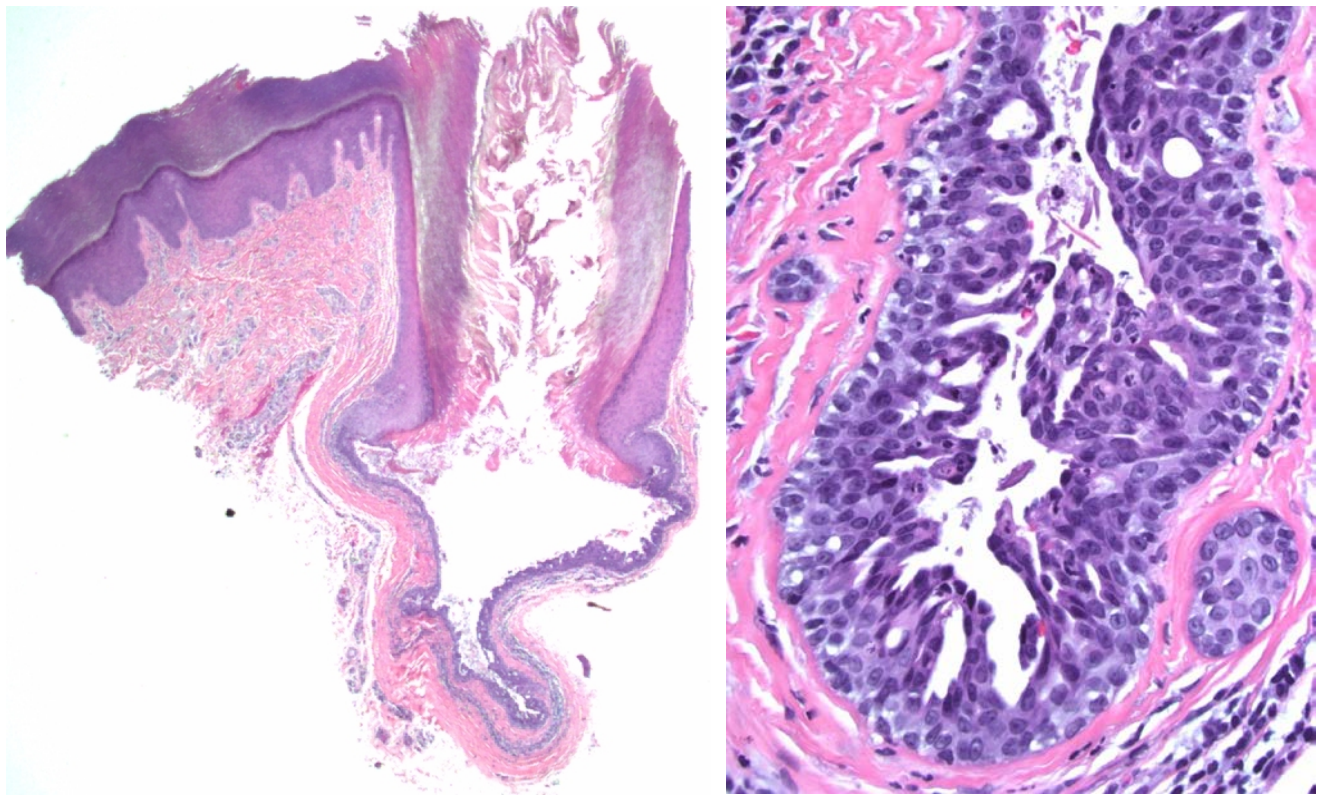
## Case synopsis

An otherwise healthy 71-year-old woman presented with an asymptomatic mass on her right 4<sup>th</sup> finger that had been slowly enlarging over the past 2 years. The patient did not recall performing any activities that would have caused a lesion to form in this particular location, but she is right-handed and enjoys gardening and knitting in her spare time.

On physical examination, there was a tan-pink, freely mobile, rubbery, 9-mm papule with a central keratotic plug located over the extensor aspect of the proximal interphalangeal joint of the right 4<sup>th</sup> finger (Figure 1). Digital range of motion was uninhibited, and neurovascular examination was normal. No similar lesions were present on either hand. The remainder of the physical examination was within normal limits. A 3-mm punch biopsy specimen was obtained for histopathology (Figure 2 and Figure 3).



**Figure 1.** A tan-pink, freely mobile, rubbery papule with a central keratotic plug located over the extensor aspect of the proximal interphalangeal joint of the right 4<sup>th</sup> finger



**Figure 2.** A cystic lesion with a keratinous plug at the skin surface (hematoxylin and eosin, 20x)

**Figure 3.** Slightly enlarged epithelial cells with some nuclear pleomorphism and rare mitotic figures are arranged in a papillary and cribriform-type architectural pattern at the base of the cystic area. No myoepithelial layer was identified (hematoxylin and eosin, 400x).

Histopathologic examination revealed a cystic lesion with a keratinous plug at the skin surface (Figure 2). Lining the cystic area were slightly enlarged epithelial cells with some nuclear pleomorphism and rare mitotic figures. At the base of the lesion, the epithelial cells were arranged in a papillary and cribriform-type architectural pattern. No myoepithelial layer was identified. An S-100 immunohistochemical stain showed scattered positivity in the lesional cells.

Based on these findings, our patient's tumor was diagnosed as an Aggressive Digital Papillary Adenocarcinoma (ADPAca) and she was referred for excision using the Mohs micrographic surgery technique. A chest x-ray was also obtained to evaluate for any potential lung metastases and was negative for any pulmonary nodules.

## Discussion

ADPAca is an adnexal tumor that is often missed owing to its rarity and nondescript appearance [1,2]. This tumor most commonly presents as an asymptomatic tan-gray to white-pink, rubbery nodule on the finger between the distal interphalangeal joint and the nail bed [1-5]. Uncommonly, the tumor can present with tenderness, ulceration, and bleeding [1,3-5]. ADPAca can be present for weeks or even years before it is diagnosed [1,3]. Clinically, ADPAca should be considered in the differential diagnosis along with calluses, knuckle pads, cysts (ganglion, inclusion, mucous), giant cell tumors, pyogenic or foreign body granulomas, hemangiomas, gout, squamous cell carcinoma, infections, and metastatic lesions [1,2].

This tumor is most often found in men with a male:female ratio of 7:1 [2]. In 2012 Suchak *et al.* [6] published a review of 31 cases. Twenty-nine of the cases occurred in males, with a mean age of 43 years (range, 14-67 years). Three cases were observed in patients under the age of 20 years. All cases involved a digit, either a finger (26 cases) or a toe (5 cases). Most cases involved the distal portion of the digit, but 2 cases occurred at the base of the digit/webspace area.

Histologically, ADPAca is characterized by a solid and/or cystic surface, a grenz zone, a mixed tubuloalveolar and papillary pattern, focal squamous metaplasia, and a fibrocollagenous stroma [1,5]. The histologic features can be quite bland with little cytologic atypia. ADPAca was formerly thought to be solely eccrine as it is typically located in areas devoid of apocrine glands [1,5]. However, a case of an ADPAca characterized by areas of sebaceous differentiation has been reported supporting apocrine differentiation in at least some instances [1].

In addition, ADPAca was previously divided into two variants: benign adenoma and malignant adenocarcinoma [1,3,5]. Lesions were considered more or less aggressive based on their degree of cellular atypia, necrosis, and evidence of invasion into surrounding tissues, vasculature, and bone [1,5]. It was later determined that both variants have a propensity for local recurrence and metastasis regardless of specific features [4,5]. Kao *et al.* observed an average recurrence rate of 48% between 2 months and 9 years following initial excision [3]. ADPAca has potential for metastatic spread to the lungs, lymph nodes, brain, kidney, bone, and retroperitoneum [3].

In the case series by Suchak *et al.*, follow-up after excision or amputation in 23 patients (range, 2 months-21 years) revealed local recurrence in 5 patients and metastatic disease in 6 patients. Of the 6 patients with metastatic disease, 1 patient had lymph node involvement, 4 patients had lung involvement, and 1 patient had both lung and lymph node involvement. In addition, 2 patients initially presented with metastases, involving a lymph node and lung, respectively. Of the 8 patients identified with metastatic disease, only 1 patient (with 2 local recurrences and metastatic lung disease diagnosed at 5 years) died 6 years after initial diagnosis. At the time of publication, 3 patients were still living up to 2 years after developing lung metastases [6].

Current treatment recommendations vary among authors and further evidence is necessary. Whereas some authors recommend digital amputation, others argue that wide excision should be considered in patients with a long-standing history of ADPAca without evidence of underlying bone invasion or distant metastasis and in cases with low-intensity expression of proliferation markers such as p53, Ki67, and p63 [1,3,4,7,8]. The question of whether or not to obtain a sentinel lymph node biopsy is also controversial. Given the delayed occurrence of metastases and the protracted course despite metastases long term follow-up is necessary. Both an annual clinical examination to evaluate for local recurrence and a chest x-ray to evaluate for lung metastasis are recommended for all patients for at least 10 years following the initial diagnosis [1,3,7].

## References

1. Frey J, Shimek C, Woodmansee C, Myers E, Greer S, Liman A, et al. Aggressive digital papillary adenocarcinoma: A report of two diseases and review of the literature. *J Am Acad Dermatol* 2009;60:331-9. [PMID: 18819728]
2. Serhat Inaloz H, Patel GK, Knight AG. An aggressive treatment for aggressive digital papillary adenocarcinoma. *Cutis* 2002;69:179-182. [PMID: 11926336]
3. Kao GF, Helwig EB, Graham JH. Aggressive digital papillary adenoma and adenocarcinoma. A clinicopathological study of 57 patients with histochemical, immunopathological, and ultrastructural observations. *J Cutan Pathol* 1987;14:129-146. [PMID: 3301927]
4. Duke W, Sherrod TT, Lupton G. Aggressive digital papillary adenocarcinoma (aggressive digital papillary carcinoma revisited). *Am J Pathol* 2000;24:775-784. [PMID: 10843279]
5. Jih DM, Elenitsas R, Vittorio CC, Berkowitz AR, Seykora JT. Aggressive digital papillary adenocarcinoma: a case report and review of the literature. *Am J Dermatopath* 2001;23:154-157. [PMID: 11285414]
6. Suchak R, Wang WL, Prieto VG, Ivan D, Lazar AJ, Brenn T, et al. Cutaneous digital papillary adenocarcinoma: A clinicopathologic study of 31 cases of a rare neoplasm with new observations. *Am J Surg Pathol* 2012;36:1883-1891. [PMID: 23026931]
7. Singla AK, Shearin JC. Aggressive surgical treatment of digital papillary adenocarcinoma. *Plast Reconstr Surg* 1997;99:2058-2060. [PMID: 9180731]

8. Hsu H-C, Ho C-Y, Chen C-H. Aggressive digital papillary adenocarcinoma: a review. *Clin Exp Dermatol* 2009;35:113-119. [PMID: 19874325]